

XXIX. *On the Structure and Development of the Skull of the Common Fowl* (*Gallus domesticus*). By WILLIAM KITCHEN PARKER, *F.R.S.*

Received November 25, 1868.—Read February 11, 1869.

Introductory Remarks.

IN my former paper, which treated of the structure and development of the skull in the Ostrich-tribe*, I proposed to write a series of such papers on the skull of the Vertebrata, and that the first of these should be confined to that of the Common Fowl.

This Bird is selected for several reasons, the first of which is the readiness with which it may be obtained; but, as far as science is concerned, a still more important reason lies in the fact that it not only forms a good halfway subject between the Ostrich and the Singing-bird, but, in a wider survey, it serves as an excellent stand-point from which to look backward to the Fish, and forward to the higher Mammalian forms.

The present paper is much more special than the last, which treated of the skull of several kinds of Struthious Birds, in just as many stages as I was able to obtain: this time an essay has been made to describe, step by step, the whole process of growth of the skull, face, and sense-capsules from the fourth day of incubation to extreme old age.

My reason for not describing the earliest stages is, that I find it done to hand already; and although I have repeatedly verified the observations of other authors on the primary condition of these parts, yet I have nothing more to add to what is already known. The latest and best description that I have seen of the primordial condition of the head of the chick is to be found in Professor HUXLEY'S 'Elements of Comparative Anatomy,' pp. 136–142, and figs. 57 A–G.

My starting-point is at that stage which is the last but one in Professor HUXLEY'S series—namely, figs. 57 F and F' (p. 138); my second stage agrees with his fig. 57 G.

In describing the Struthious skull, I did not depend merely upon what an examination of those types revealed, but had already made a large number of observations (and drawings) on the development of the skull in various Families of Birds, and also in many types from the other Vertebrate Classes. It was shown me, however, by my most judicious friend, Professor HUXLEY, that my work missed its end, in some degree, from its diffuseness, and that it would be better to get a perfect history of one type of skull, than an imperfect knowledge of any number whatever. So, to be thorough, it must content me to cultivate a small and modest plot at one time, trusting in the Unity of Nature for the value of the results, and confident that, if I can read the meaning of the Fowl's skull, my eyes will be opened to see very much more, below, above, and around.

* Philosophical Transactions, 1866, vol. clvi. part 1. pp. 113–183, pls. 7–15.

There will be now a necessity for some modification of the nomenclature used in the former paper, both with regard to the tissues and the various morphological regions; for in both these departments of my work I trust there has been some extension of knowledge, as well as rectification of former errors.

The ossific process, than which nothing is more confusing to the morphologist, has of late received a more definite nomenclature (see 'On the Shoulder-girdle and Sternum,' Ray Soc. 1868, p. 4); the new terms will be used here. These are:—(1) "ectostosis," for that tract of osseous deposit which is formed between the perichondrium and the cartilaginous mass; (2) "endostosis," for that deposit which takes place primarily in the intercellular substance of hyaline cartilage, or between the cells of simple cartilage; and (3) "parostosis," for all ossifications of mere fibrous tracts. In the paper 'On the Shoulder-girdle' (p. 10) I have spoken of a modification of the growth-process in the Warm-blooded Classes, which, until fairly understood, cost me much perplexing thought; this is where a parosteal patch of bony matter *grafts* itself upon a cartilaginous plate, setting up, first, an ectosteal deposit close upon the cartilage-mass, and then an endosteal process between the cells themselves. In this case we have the coexistence of the three types of "ostosis" to form a single osseous centre; and this state of things, so different from what is seen in the Cold-blooded Classes, and by no means to be confounded with after-coalescence, must be looked upon as a very important metamorphic modification in the skeleton of the higher types*.

As far as I can see at present, an explanation of this deliquescence, as it were, of the histological process in the formation of bone will greatly smooth the difficulties that have hitherto stood in the way of the homological part of this science; it will thus be seen that nothing is more unsafe than hasty decision upon representative parts in the various types.

There is much to be done in the study of cartilage with regard to morphological regions, and their comparison in the various types; for in some cases differentiation and chondrification are synchronous, and, in a sense, synonymous; whilst in others the fission of the cartilage does not take place until it is thoroughly consistent and even dense. This after-splitting may be perfect, or more or less imperfect; in the latter case a cartilaginous plate becomes *notched* in some instances, and *fenestrate* in others (see 'Shoulder-girdle and Sternum,' p. 4).

But as hyaline cartilage is merely to be considered a consolidated primordially cell-mass, and a very fast-growing tissue also, it is not surprising to find it running riot over a large number of morphological territories (*op. cit.* p. 4): this takes place to the greatest extent in the lowest and most generalized types, which, however large (even gigantic) they may become, are nevertheless mere embryos throughout life, in respect of their morphological development.

The sharp distinction between the skull and the vertebræ is well seen in this—that

* In the Amphibia no definite line can be drawn between parastoses and ectostoses, and the most typical endosteal deposit is merely an ossification of that part of the fibrous laminae which immediately encloses the cartilage.

whilst the whole of the notochordal region of the skull belongs to the occiput, this region, if it had suffered fission, would have sufficed to form a whole series of vertebræ. Thus that cranial region which has most of the vertebral nature in it cannot answer to one actual vertebral segment, seeing that it contains (subjected to the law of a new type of growth) several potential segments.

As the skull proper cannot be shown to conform to the vertebral column, so neither can the facial arches be put into the same category with the ribs; for the present they must wait until their development has been worked out perfectly in a considerable number of Vertebrate types: I mention this to excuse myself from all controversy concerning them in the present communication. The mouth and the fauces (the faucial region is of great extent in the Cyclostomous Fishes) are hedged in by what are evidently one class of cartilages; these may be either free rods or fenestrate plates: I propose to call these the "facio-faucial" skeleton.

These bars extend beyond the skull, and are very variably attached to it—in some of the lowest Vertebrates (as the Cyclostomi, the Chimæroids, and the Lepidosiren) being, anteriorly, mere outgrowths of the skull, whilst in the higher Classes they have a very independent development. In the Bird there are only three poststomal arches developed, whilst in the gill-bearing "Ichthyopsida" there are several.

It seemed to me to be necessary to preface the description that is to follow with these remarks; but I must now let the Bird's head tell its own tale. What there may be in this account which will not harmonize with the descriptions given in the former paper will be duly noted from time to time, and the reasons for a modified nomenclature will be given.

*Structure of the Chick's Skull, First Stage.—Head of Embryo 3 lines long:
4th Day of Incubation.*

The appearance of the chick's head and face on the 4th day, as seen from below, is well shown in Professor HUXLEY'S figure (*op. cit.* p. 139, fig. 57 F); another figure (F') shows the cartilaginous cranium of the same. In Plate LXXXI. figs. 1 & 2, I have given what appears to me to be the state of things at this early stage; fig. 1, however, the lower view, is somewhat diagrammatic, as I have in it anticipated the differentiation of the pterygo-palatine bar (*p.g.pa.*) from the next stage; these show the parts as magnified 9 diameters.

The visceral clefts (Plate LXXXI. fig. 1, 1, 2, 3) are still evident; and the fronto-nasal process (*f.n.*) is, as yet, free at its sides, so that the anterior nares (*n.*) are still mere clefts—the foremost or prestomal clefts. The great mouth-cleft (*m.*) is four-sided, with concave sides and produced angles; and the anterior angles run into the nasal clefts: these clefts, and their intervening arches, all evidently belong to one category; the arches surround, and the clefts open into the oro-faucial cavity.

To show the character of the skull-floor, a chick's head at this stage has been sliced completely through, horizontally (fig. 2), the second and third cerebral vesicles have been completely removed, and the first vesicle, the subdividing rudiment of the hemispheres, has had its upper half removed; the lower half of each eyeball is shown also *in situ*.

The notochord (*n.c.*) is seen to be half the length of the head, or a line and a half, and to reach within a very slight distance of the pituitary space (*p.t.s.*): this *relative* but not *real* retreat of the notochord now bespeaks the first appearance of the post-pituitary part of the basisphenoidal region. The notochord is clubbed at its fore end, it then is narrower, then thicker between the auditory sacs (*c.l.*), and is again somewhat diminished as it passes into the atlantal region.

The broad, thick plate of cartilage (shown as somewhat sliced away, horizontally, above the cochlear cavities, *c.l.*, in the figure) which lies right and left of the notochord, is the "investing mass" (*i.v.*) of RATHKE*. At this stage the "investing mass" is rapidly passing from simple cartilage into the solid hyaline variety; it is most dense nearest the notochord, and becomes more and more gelatinous as it is traced upwards into the wall of the cranium. Hence the commencement of the spinal chord is not as yet bridged over by a cartilaginous superoccipital plate, and the cartilage in which the upper part of the auditory sacs are imbedded is still in a soft condition. Here it may be at once remarked that no separate cartilaginous auditory capsule is formed in the chick (such as can be plainly seen in the Tadpole), but the two moieties of the investing mass grow into one continuous "occipito-otic" cartilage†. At a small distance in front of the cochlear cavity (*c.l.*) the investing mass is suddenly narrowed: this is where the fifth nerve passes out; and this nerve divides the occipito-otic region from the posterior sphenoidal. At most, the clubbed anterior end of the notochord is wedged into the very end of the basisphenoidal region; and afterwards it will be seen that the whole of its cranial portion becomes the axis of the basioccipital. All the nerves between the fifth cranial and the first spinal are related to the investing mass; so that even if it were ceded that the occipital region is essentially vertebral in its nature, yet it must then be looked upon, not as one segment, but the non-segmented counterpart of several. On each side of the end of the notochord the investing mass at first grows outwards in an angular manner (shown in Professor HUXLEY'S fig. 57 F', and in Plate LXXXI. fig. 2, *l.g.*); these angles are the rudiments of the cartilaginous "lingulæ sphenoidales;" these parts arise from the *roots of the trabeculæ*‡.

* RATHKE'S account of this part, in his work on the Snake (*Entwicklungsgeschichte der Natter*, 1839), is thoroughly correct; I will give it as translated by Professor HUXLEY (*Croon. Lect.* p. 56, and *Elem. Comp. Anat.* p. 237):—"The differences between the basis of the skull and the vertebral column in the earliest embryonic condition are:—(1) That, round that part of the notochord which belongs to the head, more of the blastema, that is to be applied in the spinal column to the formation of the vertebræ and their different ligaments, is aggregated than around the rest of its extent; and (2) that this mass grows out beyond the notochord to form the cranial trabeculæ."

† The periotic mass, which becomes perfectly segmented from the occipital sclerotome in many Mammals—but in them only in the last or osseous stage of growth—is never cloven in any degree from its surroundings in the Fowl; it is, however, partially cloven off in many Water-birds, by a fenestra which appears between the epiotic and the lower edge of the superoccipital.

‡ I think that RATHKE'S term "middle trabecula" may be dropped; it appears to me to be merely the gelatinous precursor of the "posterior clinoid wall," and has nothing in common with the basal paired trabeculæ.—See HUXLEY'S *Croon. Lect.* p. 57.

The trabecular roots are transversely crested (the somewhat diagrammatic figure 2 shows this but feebly); this is the angle of that bend formed by the early skull called the "cranial flexure" (HUXLEY, *Elem.* p. 137).

This crest becomes very large, and is persistent, notwithstanding the after-straightening of the cranio-facial axis; it is connected with the high "posterior clinoid wall." The anterior, smaller moiety of the cranio-facial axis is bent, first at an acute, and afterwards at an obtuse angle; it is becoming obtuse on the fourth day; all this fore part is formed by the "paired trabeculæ:" these are flat bands of, at present, soft or simple cartilage; they are now about $\frac{1}{100}$ of an inch in width, and are moderately thick in proportion. These bands are gently curved outwards at first, to enclose an elegantly ovoidal membranous space, the pituitary space (Plate LXXXI. fig. 2, *tr.*, *p.t.s.*); this space is enclosed by the early coalescence of the symmetrical bands in front of it; and this coalesced part is nearly equal in length to the pituitary region. The trabeculæ maintain a similar size to their extremities, but at their coalesced part they have begun to form an arched outgrowth on each side; these symmetrical expansions are the rudiments of the "aliethmoidal" and "aliseptal" cartilages of the nasal labyrinth. This broadened ethmoidal part of the trabeculæ is bent backwards in a rounded manner on itself, so that the remaining part of the trabeculæ lies on a lower plane, parallel with the pituitary floor, and with the free ends looking directly backwards (Plate LXXXI. fig. 1, *c.tr.*); the free ends are slightly divergent, and are separated by a space about equal to their own width. These free retral ends of the trabeculæ are the "trabecular horns;" they form the soft skeleton of the "fronto-nasal lamina" (*f.n.*), and are developed into the "alæ nasi" or "alinasal laminae," and do not coalesce to form the intermaxillary axis or "prenasal cartilage," as I once supposed (see former paper, pp. 121 & 122). The "fronto-nasal laminae" will have united with the "maxillary rudiment" (*m.r.*) to enclose the anterior nares (*n.*) before the "intermaxillary axis" will be evident: this will be described in the next stage. Here one may pause to remark that the nasal labyrinth is formed continuously with the primordial cranium, just as is the case with the otic capsule; any segmentation that may appear afterwards will thus be a secondary morphological process; and thus the eyeballs are sharply distinguished from the other sense-capsules, which, from their undefined skeletal growth, and their relations to the visceral arches, form a most puzzling problem to the morphologist. It will be seen from this description that the "anterior sphenoidal region" is scarcely at all represented at this stage; for the somewhat narrowed waist formed by the trabeculæ immediately in front of the pituitary body is all that has yet appeared of the "anterior clinoids," the prepituitary part of the basisphenoid, and the presphenoid. This latter part is, indeed, feebly represented in the adult Bird, and only occupies an angular space above the junction of the perpendicular ethmoid with the basisphenoid. At present there is a curved, clubbed, subocular bar, the "maxillary rudiment" (*m.r.*), which comes very close at its anterior clubbed end to the "fronto-nasal lamina," but has not yet united with it to enclose the anterior nares (*n.*). In fig. 1 the cartilaginous differentiation of

the pith of this bar, my study of which has been from fine transverse sections in the next stage, is somewhat anticipated. The axis of this soft bar is converted into the palatal and pterygoid rods (*pa.*, *p.g.*); and from the outer edge of each of these bent clubs a lamina grows downwards (see HUXLEY, *op. cit.* fig. 57 G, *l.*), in the internal fibrous stroma of which the maxillary and jugal bones are afterwards formed. The axis of the maxillary rudiment never has any cartilaginous connexion, anteriorly, in the Bird, with the ethmoidal lamina (prefrontal); and, behind, the chondrification of the pterygoid portion of this axis is quite distinct from, and much later than, that of the "quadrate." Here we see that the "subocular arch" is much modified from what is seen in the Ichthyopsida.

The primordial skull figured by Professor HUXLEY (fig. 57 F') must have been from a less mature embryo than that which I am here illustrating as my first stage; for in that figure the quadrate (*qu.*) is shown as continuous with the antero-external part of the "investing mass." In my specimen (Plate LXXXI. figs. 1 & 2, *qu.*) the quadrate is already a very distinct tuberos mass of consistent cartilage, rapidly becoming hyaline. MECKEL'S cartilage (*m.k.*) is also very distinct and solid, and its articular end has a sinuous face, answering to that on the lower end of the quadrate; whilst the posterior and internal angular outgrowths have already appeared (fig. 1, *m.k.*). These Meckelian rods are very short in proportion to their thickness, are gently curved forwards, and nearly meet at the mid line by rounded ends. These axial parts of the first pair of poststomal laminae are surrounded by very delicate blastema—the parent tissue of the splints, muscles, and skin of the lower jaw; the outline of this primordial mandible is emarginate at the mid line. That which is perhaps the most noteworthy in the first poststomal arch at this stage is its position with regard to the auditory capsule; its pier, the quadrate, is segmented from the antero-external angle of the investing mass, directly in front of the periotic capsule, and opposite the junction of the anterior with the middle third of the cranial part of the notochord; whilst the fifth nerve (5) passes out in front of it. This normal position is lost and then regained before the chick is ripe. Close behind the quadrate there is the first poststomal cleft (1), ready to become converted into the complex tympanic cavity.

In the obtuse angle formed by the Meckelian rods, and lying on a higher plane than those rods, we find the distal arrested cartilages that belong to the second poststomal arch; these are the "cerato-" and "basi-hyals" (Plate LXXXI. fig. 1, *c.h.*, *b.h.*). At present these are merely thickened masses of blastema, their outline being somewhat indistinct, as the young cells of which they are composed are not sharply separated from the formative substance which will become their perichondrial investment. The cerato-hyals (*c.h.*) are even now only half the size of the mandibular rods; but this is the greatest *relative* size they attain, for they diminish much afterwards.

There is no proper skeletal substance between the top of the cerato-hyals and the tissue that forms the auditory "columella" (stapes): this latter part is not differentiated sufficiently to be described at present; it is both *late* in appearance, and also very minute.

The basi-hyal (*b.h.*), although formed in the united edges of symmetrical laminae, is, even as a defined mass of thickened blastema, quite azygous; it is tear-shaped, the narrow end lying between the lower ends of the cerato-hyals; this basal part is better defined than the arches, and chondrifies first.

Behind the second fast-closing cleft (2) there is now to be seen a pair of well-defined rods, nearly as large as the Meckelian cartilages, and as early in their chondrification; these are the "branchials" (*c.br.*), answering to the first branchial arch of the Ichthyopsida. There is a less distinct upper piece, pointed and small (*e.br.*), and a delicate streak of ill-defined blastema behind and between (*b.br.*); this latter is formed into the long slender so-called uro-hyal, the counterpart of the "basibranchial band." Behind the branchial arch a chink still indicates the place of the third visceral cleft (3)*.

At this early stage the arch of the tongue has begun to lie *within* the mandibular arch, just as the lessened first branchial arch comes to lie within the massive hyoid arch in the Osseous Fish.

Already the third visceral arch of the Bird has outgrown the second—a state of things universal in the Class of Birds.

Before leaving this stage, it may be noted, as instructively parallel with that which is persistent in Cartilaginous Fishes, that there is no exo-skeleton, no præmaxillæ, maxillæ, dentaries, angulars, or the like; the mouth and unenclosed nostrils are entirely *below* the head: these, and the rudimentary tympanic cavities, open freely into each other, and are all lined with dermal tissue, which is, as it were, tucked in between the visceral laminae from the outer surface of the head.

Second Stage.—Head of Embryo from 4 to 5½ lines long: 5th to 7th Days of Incubation.

In the course of twenty-four hours great changes have taken place in the chick's skull and face. In an embryo with a head 4 lines long (Plate LXXXI. fig. 3, 6 diam.), a vertical section shows the notochordal region to be shorter than that formed by the trabeculæ; and this anterior moiety of the cranio-facial axis has become much straighter, the head having now to a great extent recovered from the "cranial flexure." The "investing mass" has become more solid; and a distinct swelling on each side, posteriorly, shows how the occipital condyle (*o.c.*) is formed—very reptilian, however, in shape, at first. On each side, a thin soft lamina of cartilage (*e.o.*) is growing up behind the third cerebral vesicle (*c.v.* 3); this is the commencement of the occipital plane. At the angle formed by the bending of the primordial cranium upon itself, a transverse crest of cartilage has grown rapidly upwards and backwards; this, the "posterior clinoid wall," protects the pituitary body behind, and lies in the midst of a quantity of delicate stroma, which

* Till lately I have partly followed Professor OWEN's nomenclature for the third poststomal arch of the Bird, calling its moieties "thyro-hyal." (See Brit. Assoc. "Report on Archetype," 1847, p. 295, fig. 23, where the lower piece is identified as the "hypobranchial" of the Fish, and the upper is called "cerato-branchial.") I find, however, that the "thyro-hyals" of the Batrachia and Mammalia are merely retral "hypobranchial" processes; and I cannot consider the lower piece in the Bird to be other than the "cerato-branchial."

eventually becomes the fore part of the "tentorium cerebelli." The internal carotid artery (*i.c.*) is seen to be entering the skull in front of this wall.

The greater part of the investing mass may now be treated of as the basioccipital region (*b.o.*); anteriorly the nascent fibrous tissue is thickening below this part to become a bed for the deposit of the basitemporal.

The pituitary space is now much foreshortened, very deep, and is indicated in the figure by the entrance of the internal carotid artery (*i.c.*); the cartilage has become high, even below and between the optic nerves (2); and close in front of the pituitary body the anterior clinoid ridge (*a.cl.*) has commenced. But in front of the optic nerves the greatest and most sudden change has taken place, the very short broad waist between the pituitary space and the rudimentary ethmoidal alæ shown in fig. 2 being at this stage greatly elongated and altogether developed into a high crest: this is the ethmo-presphenoidal plate (*p.sp., eth.*). This plate, which is rapidly passing into hyaline cartilage, is somewhat higher behind than before, is nearly straight above, is oblique behind, above the optic nerves, concave below, and has a gently convex margin in front.

The alæ of the nasal labyrinth are not shown in this section; but above and below the line where these have been cut away on the left side, two projections are seen. The upper of these is the retral spike, in which the ethmoid ends behind above the olfactory crura*; whilst the lower process is one of the greatest importance in the morphology of the face, it being the prenasal or snout-cartilage (*p.n.*). This part, which is the endoskeletal axis of the premaxillary region, grows at first *backwards* as well as downwards, having the same direction as the "fronto-nasal lamina," and being an azygous outgrowth from the crest which forms between the trabecular cornua—the rudimentary septum nasi, continuous with the ethmo-presphenoidal plate. The cornua themselves, as I have already asserted, develop themselves into the alæ nasi. This condition of the prenasal cartilage is like what is seen in the ripe embryo of the Green Turtle (*Chelone mydas*); in that animal, however, it is less rounded in shape, and projects further downwards, forming a soft core to the premaxillaries†. The thick arcuate inferior edge of the ethmo-presphenoidal plate has already begun to be underlain by that fibrous stroma which afterwards thickens very much between the basis cranii and palatal skin to form a nidus for the rostral part of the "parasphenoid."

Below, and on each side of the basis cranii, the maxillary rudiment has begun to send downwards the facial lamina in which the maxillary and jugal bones are afterwards developed, and to have a more distinct rod on the inner side, which becomes the palatine (*pa.*) and the pterygoid (*p.g.*); but this will be best studied in a chick a day or two

* This spike is called "crista galli" (*cr.g.*) in my former paper; but Professor HUXLEY has shown me recently that there is nothing in the Bird which answers to that plate, save that notched and grooved part of the perpendicular ethmoid which lies exactly between the olfactory nerves; so that, practically, it may be said to be undeveloped in this Class.

† Professor HUXLEY is strongly inclined to believe that the "trabeculæ," from their roots, are in reality the foremost (and of necessity the innermost) pair of visceral arches.

older. I shall also leave the mandibular (*m.k.*) and hyoid cartilages (*h.*) for description from an older embryo.

The development of the parts goes on very rapidly, so that when the head is 5 lines in length a much clearer idea of the structure of the parts can be obtained. A vertical section, left-hand of the septum, of such a skull is shown in Plate LXXXI. fig. 4, and a side view in fig. 5, both magnified 6 diameters; in these views the cerebral vesicles are not figured.

A low ornithic type, such as is persistent in the Ostrich, is now attained. I have already had to compare the skull of the chick with that of a Plagiostome and of a Turtle; after the Struthious stage has been passed, many of the higher ornithic specializations will rapidly appear.

The straightening of the cranio-facial axis has gone on so as to make the face much more prognathous; and the axis of the anterior part of the face (*p.n.*) is especially altered, so as to have already taken on an ornithic character; the boundary, also, between the nasal and orbital regions can now be seen. One landmark has become especially visible, on account of the denser condition of the cartilage; this is the bridge for the nasal nerve (*n.n.*): in the adult bird this is seen near the free postero-inferior angle of the nasal septum. For some distance behind this bridge the cartilage continues thicker than we find it between the eyeballs; the larger, thinner, posterior part of the cranio-facial axis answers to the whole of the presphenoid and the posterior or interorbital part of the perpendicular ethmoid. The grooves for the olfactory nerve (1) can be well seen; and the retral spike of the ethmoid surmounting the nerve-grooves has become much more defined, and has begun to take a backward direction instead of the vertical and *human* direction it had a day or two before (see Plate LXXXI. fig. 3, *eth.*). This is now the highest part of the cranio-facial axis, whereas the presphenoid was the highest in the last embryo. The whole base of the prepituitary part of the primordial skull is very thick and rounded; and its thickness from side to side increases in the prenasal cartilage (*p.n.*), which now shows itself to be a very fit model on which the premaxillaries of any type of Bird might be formed; in no Bird whatever, let the shape of its face be what it will, is the type of the first model or platform wholly lost, although in every case the primordial structure (into the type of which they were cast, as it were,) undergoes very early wasting. Between the palatal skin below, and the still very arcuate skull-base above, a considerable mass of stroma is formed, which is cordiform in section, and which soon becomes the seat of the rostral (or anterior parasphenoidal) ossification: this rostral stroma (*r.st.*) is shown in fig. 6, magnified 12 diameters. This tract is composed of thin-walled baggy cells, which never chondrify (except on the surface in certain birds, as the Psittacinæ and Ardeinæ), but develop either into bone (internally) or into periosteum (externally). In fig. 7 the differentiation of the tissues that underlie the skull-base in the posterior ethmoidal region is shown, magnified 160 diameters. The ethmoid (*eth.*) is already formed of ordinary hyaline cartilage, with abundant intercellular substance and tear-shaped cells; next below this is a tract of very delicate granular

stroma (*gr.st.*), then a deep layer of the larger-celled young connective tissue (*r.st.*), and below this the epithelium of the palate (*ep.l.*). The aggregation of a thick bed of nascent fibrous tissue between the skull-base and the palate and fauces, and the conversion of the greater part of this mass into bone in a very early stage, is common to many of the Vertebrata—for instance, the Ganoid and Teleostean Fishes, the Amphibians and Ophidians; the Lizards show this structure much more feebly.

The thickened and solidified postpituitary part of the basis cranii shows this superfacial mass—the seat of the “basitemporal” ossifications (Plate LXXXI. fig. 4, *bt.st.*); the fibrous layer thins out towards the occipital condyle.

The parts of the primordial skull can now be made out more clearly; the exoccipital lamina (*e.o.*) is growing upwards to meet its fellow in the superoccipital region (*s.o.*), and thus enclose the spinal chord.

Above the meatus internus (*m.i.*) the anterior semicircular canal is seen to bulge inwards and to grow backwards; below and behind the meatus is seen the eighth nerve (8), below and in front of it the cochlear elevation (*c.l.*) nearing the mid line. The low anterior clinoid elevation (*a.cl.*) and the high posterior clinoid wall (*p.cl.*) are well seen, and the notochord (*n.c.*) mounting up between the moieties of this wall, which now begin to coalesce across their middle; they do not unite, however, either above or below. A thin lobe of cartilage ascends the side wall of the skull outside and behind the posterior clinoid wall; this is the rudiment of the alisphenoid (*a.s.*); it is connected with the periotic capsule by a bridge of cartilage, which arches over the trigeminal nerve (5). The internal carotid artery (*i.c.*) finds its way into the pituitary space (*p.t.s.*) through a mass of soft fibrous stroma.

On the outer side of the primordial skull other parts can be seen; this view is given in fig. 5; here the facial arches are also shown. The nasal labyrinth develops with extraordinary rapidity, so that by the end of the first week all the main parts can be seen. Anteriorly the flat trabecular horn has expanded into the alinasal cartilage (*al.n.*), with its enclosed turbinal or vestibular flap (*n.t.*); behind this is the aliseptal region (*al.s.*), enclosing the inferior turbinal coil; and posteriorly there is the aliethmoidal lamina, which is continued downwards between the nose and the eye as the anteorbital plate or “pars plana” (*p.p.*)*. Fig. 6 shows a transversely vertical section (12 diam.) through the ethmoidal region, immediately in front of the anteorbital laminae (*p.p.*), which are seen to be continuous with the aliethmoidal coil (*al.e.*), and to have no distinct “middle turbinal” outgrowth on their anterior face. In this view part of the cartilaginous sclerotic (*scl.*) is shown, and the section is also made through the middle of the palatine bar (*pa.*). Here is seen the true “schizognathous” condition of the palate; the mouth-

* The “pars plana” is continuous with the rest of the nasal labyrinth in all Birds; my earlier studies of these parts misled me; and in my paper “On the Osteology of the Gallinacea” (Zool. Trans., 1863, vol. v. p. 179) I spoke of this plate as being “autogenous in its cartilaginous state, as well as in its ossified condition.” In the paper on the Ostrich’s skull (p. 127 *et seq.*) this part was described as continuous with the rest of the nasal labyrinth.

cavity being continuous, between the narrow palatines, with the plicated nasal sac, although the chink between the rostral stroma (*r.st.*) and the anteorbital plate is very narrow.

Seen from the outside, the alisphenoid (*a.s.*) shows an oblique crest; this is the post-frontal plate (*p.f.*); it is largely developed in Fishes, but entirely absent (as is also the alisphenoid itself) in the Lizards and Chelonians. Infero-laterally the cartilage of the auditory region is scooped to form the tympanic cavity; but at present this part is filled with a gelatinous stroma, which grows very rapidly for a week or two and is then absorbed. The horizontal (*h.s.c.*) and posterior (*p.s.c.*) semicircular canals now shine out through the occipital cartilage, and the exoccipital region (*e.o.*) has developed its tympanic wing.

The quadrate cartilage (*q.*) has received a large and peculiar development, and, like the uncloven orbito-nasal septum, has attained a struthious condition. Anteriorly the little nodule figured in the First Stage (Plate LXXXI. figs. 1 & 2, *q.*) has grown into an arched blunt-pointed "orbital process;" inferiorly it has become a thick bar with two oblique condyles for articulation with the mandible; whilst posteriorly it has grown into a long arched crus, which not only articulates with the periotic capsule, above the junction of the prootic and opisthotic regions, but also with the exoccipital in front of the root of its tympanic wing. This articulation is shown in fig. 5^a (16 diam.) and fig. 5 (6 diam.), and it is seen to answer to what is depicted in my former paper on the Ostrich-tribe (Plates VII.-XIV.); in the Tinamou (Plate xv. fig. 1, *q.*) some recovery of the original position is attained*.

Where the quadrate cartilage articulates with the cranium, the side wall is somewhat scooped; but further down two small clefts appear, which, however, never go beyond the condition of fenestræ: these are the "fenestra ovalis" and "f. rotunda" (or f. vestibuli and f. cochleæ). The fenestra ovalis is, properly speaking, an aperture in the fundus of the cup-shaped articular cavity in which the head of the stapes (Plate LXXXI. figs. 5 & 5^a, *st.*) is articulated, and is morphologically like the acetabular fenestra of the Bird, and the glenoid fenestra of the *Proteus* and *Cryptobranchus* (see 'Shoulder-girdle and Sternum,' pl. 3, figs. 1 & 3, *gl.*).

From the first the parts of the hyoid arch are very inferior in size and later in development than those of the mandible; at this stage, after the quadrate has undergone so much modification and is so well chondrified, the stapes can only now be distinctly seen; and its outgrowths are mere bud-like projections from the main shaft. It is seen that the

* I must insist on the *zoological* importance of this condition of the quadrate, which is temporary in the Fowl and persistent in the Struthionidæ: in a large number of Birds the head of the quadrate, instead of being single as in the Struthionidæ and in this early stage of the Fowl, is divided into two short crura, one of which (the antero-external) keeps its normal place on the prootic, whilst the postero-internal crus retains the acquired (struthious) relation with the exoccipital ala. The Parrots come nearest to the Fowls in the forward position of both the articular facets, which are separated by a very narrow tract; in both these types the inner is slightly *behind* the outer.

head of the quadrate projects some distance *behind* that of the stapes; but this truly ornithic modification is, exceptionally, only of short duration in the Fowl.

At present the stapes is relatively a much more massive bar than afterwards; seen from the front and side (Plate LXXXI. figs. 9 & 10, 24 diam.) it appears as a flattened rod, curved forwards, with an oval head and a trilobate flattened base, the leading ray of which is most curved forwards and outwards*.

There is still a considerable tract of cartilage to be described in the proximal part of the face, namely the pterygo-palatine bar. The prenasal cartilage (already described) is an azygous prestomal counterpart of the Meckelian rods, although it does not become cloven from the primordial skull, and is never related to a free proximal cartilage, like the Meckelian bars; but the pterygo-palatine bar is perhaps the most difficult part of the cephalic skeleton to interpret. Seeing its primordial independence of the skull in the chick, and noting its early subdivision into a posterior short, and an anterior longer bar, it seems to be very feasible to compare its two divisions with the quadrate and the Meckelian rod. It lies above and *in front* of the great stomal cleft, much as the mandibular rods lie below and behind; but its point of suspension is a great difficulty; and the mind of the observer will revert to its various development in the Ichthyopsida. In the Chimæroids and in the Lepidosiren this part is not only continuous with the skull-base, but also with the prenasal cartilage in front, and with the common pier of the mandibular and hyoid arches (MÜLLER, 'Myxinoids,' pl. v. fig. 2; and HUXLEY, *op. cit.* p. 196, fig. 78, and p. 209, fig. 85); in the Frog the palatine passes, anteriorly, directly into the prefrontal cartilage (*op. cit.* p. 216, fig. 87). In the chick, the position of the pterygo-palatine bar is below and external to the basis cranii (figs. 5 & 6), from which it is separate from its first differentiation; it has, however, a much more intimate connexion with the quadrate, but is well differentiated from it on the fourth day (Plate LXXXI. fig. 1, *p.g., q.*), and, indeed, has very different histological characters. The suspensorial parts of the pterygo-palatine bar are feebly developed, and are late in their appearance; these come to be below the optic foramen for the pterygoid, and below the prefrontal plate for the palatine: these will be described hereafter. At present the relation of the palatine bar to the prefrontal plate (fig. 6, *p.p., pa.*) is totally unlike what is seen in the Frog; for, between the two, there is not only the thick fibrous stroma in which the delicate palatine bar is imbedded, but also the open channel which connects the cavity of the mouth with the interior of the nasal labyrinth. I would much rather interpret this bar by its specialized and freed condition in the Bird, than by what is seen in the low Vertebrate types, where the rampant growth of cartilage masks the proper morphological boundaries; and yet even in the high type the bar would seem to bear two interpretations—namely, that it may be a single arch, like the mandibular, the pterygoid being the equivalent of the quadrate; or, on the other hand, the pterygoid and the palatine may be merely the proximal parts of two arches, neither of which has

* This bar must be studied at an earlier stage; in Cyclodont Lizards and Chamæleons the trilobate (hyoid) portion is quite distinct from the clubbed periotic rod.

a free descending ray; but I am extremely doubtful about the latter interpretation, and strongly incline to regard the mandibular, pterygo-palatine, and trabecular rays as true serial counterparts.

The true histological growth and development of the pterygo-palatine bar has cost me much labour; only by examining sections made at many stages, and by seeing these under very high powers, has the meaning been made apparent. In a fresh-made section at this stage (Plate LXXXI. fig. 6) the tissues composing the ethmoid (*eth.*), the rostrum (*r.st.*), the palatine (*pa.*), and the sclerotic (*scl.*) do not appear very much unlike when seen by low powers; afterwards their differing characters may be seen. The cells composing the sclerotic (*scl.*) are smaller than those which make up the ethmoid (*eth.*); but they rapidly form hyaline cartilage; and both these tracts are more translucent than the rostral stroma or the cells composing the palatine. The latter can, however, be seen to transmit the light better than the rostral mass; and by the use of high powers (320 diam.) the structure of the rod becomes sharply distinguished from the nascent cellular tissue in which it is imbedded, and also from the more advanced connective-tissue cells of the rostrum. Much the greater part of the palatine bar (fig. 11) is composed of delicate, sharp-ended, fusiform cells of simple cartilage*, having large granular nuclei; but the pith of the bar is composed of still more delicate and smaller cells having an oval form, and without apparent nuclei—at least as seen magnified 320 diameters; it is this pith which is the first to ossify; and the transformation of the simple cartilage into bone is so rapid as to give the deposit the appearance of a membrane bone†.

The further development of the palatine bar will be described hereafter; and the pterygoid (*p.g.*), which is at present composed of simple cartilage similar to that of the palatine region, will be considered at the same time.

There now remain for description the free part of the facial (poststomal) arches; and the kestones that complete them. There is no keystone to the mandibular arch, which

* Professor HUXLEY is disposed to look upon what I call "simple cartilage" as merely "indifferent tissue."

† For many years the development of the pterygo-palatine bar in the Sauropsida and Mammalia has been a great difficulty to me, as with moderately high powers, at stages more advanced than the one under notice, I could not well see how the main part of the bar differed from a membrane bone; yet I had discovered the existence of hyaline cartilage in several parts of the bar in Birds. In the Passerinae and some others, the broad transpalatine angle is not ossified by the proper palatine centre, but by a separate endosteal deposit, and that long after the main bar, so that the simple cartilage gains time for a plentiful intercellular deposit. In the Woodpecker (*Picus viridis*) the inner edge of each palatine does not ossify from the main bony rod, but develops into hyaline cartilage, coalesces with its counterpart of the other side, and then slowly and feebly ossifies by endostosis, this centre being, properly speaking, an azygous "mesopterygoid." Hyaline cartilage may be found at the pterygoid end of the palatine proper in certain Birds (e. g. *Caprimulgus*); then it also appears in the counterpart facet in the pterygoid; it is always present on the quadrate end of the pterygoid; and whenever this bone articulates with a basipterygoid process, a meniscoid plate is developed on the corresponding part of the pterygoid. In many Reptiles (Lacertians and Chelonians) the posterior part of the subocular cartilage chondrifies and develops into a straight rod, which is obliquely situated above the fibrous or main pterygoid; ossifying separately, it becomes the so-called "columella:" the pterygoid of the higher Birds is more nearly related to this than to the underlying fibrous bone.

is entirely composed of the articulo-meckelian rod. This rod (Plate LXXXI. figs. 5 & 12, *m.k., ar.*) is a gently curved very solid bar of hyaline cartilage; it bulges and narrows two or three times, but does not greatly diminish in size even at its rounded anterior end.

The articular portion is scooped in harmony with the swellings on the lower face of the quadrate; and from this part there project two finger-shaped processes; these are the internal (*i.a.p.*) and posterior (*p.a.p.*) angular processes. Already these processes show the type to which the bird belongs; for they have a peculiar development in the whole "Gallo-Anserine" series, and in one or two *mixed* cognate forms (for instance, in the Flamingo); they attain their most extraordinary development in the "Tetraonine" subgroup of the Gallinæ, and especially in *Tetrao urogallus*.

In a somewhat earlier stage (head of embryo $4\frac{1}{2}$ lines long, see Plate LXXXI. fig. 12, 12 diam.), notwithstanding the rapid elongation of the Meckelian bar (*m.k.*), these processes are scarcely more developed than in the Struthious Birds (see former paper, Plates VII.-XIV.), and the ends of these short processes are very knobbed. In this instance the nascent connective fibres surrounding these parts were quite free from osseous deposit, and so was the rest of the primordial skull, now representing the Cartilaginous Fishes; but in one a day or so older the splint-bones had commenced outside the perichondrium of the Meckelian rod (fig. 13, *su.*). Here the upper view of the articular part of the mandible shows that it is a bifurcating or partially double ray, which develops a groove-and-ridged articular surface on its upper face, at the point of bifurcation.

The next poststomal cephalic arch (the hyoid) is slow of growth, feeble in development, and rapidly gains an enclosed position, instead of maintaining its proper surface parallelism with the mandibles. The arches themselves (the cerato-hyals) are mere distal rudiments, such as we often see in the costal arches, a long space of mere fibrous tissue intervening between the arch and the pier. Their chondrification is *late*, as a correlate of their feeble growth. A somewhat earlier and stouter piece of cartilage appears between and behind them, the basi-hyal (*b.h.*); it is tear-shaped, with the pointed end foremost. Behind this, with its pointed end looking backwards, a longer and narrower piece appears; this is the so-called uro-hyal (*b.br.*), an azygous bar answering to the basi-branchial series of the Fish-class generally, and not to the "uro-hyal" of the Osseous Fish—which is a fibrous bone, a "basi-branchiostegal." The first branchial arch of the Fish is here represented by a stout ray segmented into an upper smaller (*e.br.*), and a lower larger segment (*c.br.*): these are they that suffer such extraordinary development in the Humming-birds and Woodpeckers, and which in typical birds always surmount the occipital plane, whilst in the typical Struthionidæ (*op. cit.* Plates VII.-XIV.) they are arrested at the stage here described in the chick.

Third Stage.—Head of Embryo from 8 to 9 lines long: middle of 2nd Week of Incubation.

Henceforth my work will fill both hands at once; for now the skeleton of the skin and its enfoldings will everywhere present itself side by side with the proper primordial

parts of the skull-building; and, unlike what the easier problem of the lower types, as a rule, presents, we shall see the outer works growing upon and grafting themselves into the inner works, and afterwards both the skeletons becoming compacted together and growing into the simplest brain-casket in one part, and the most mobile prehensile organ in the other.

This third stage is in some respects parallel with what is seen in certain Teleostean Fishes, in which there is a free development of the cartilaginous endoskeleton, which is but little ossified, whilst the secondary or splint-skeleton is very frail and delicate; such skeletons are possessed by the Lump-fish (*Cyclopterus*), and by the Salmon.

In the illustrations of this stage the figures are drawn and magnified from embryos with the head two-thirds of an inch long; here several of the ectosteal patches have appeared within the perichondrium, and the splint-bones are all present. The primordial skull, when stripped of its infoldings and seen from below, presents the appearance shown in Plate LXXXII. fig. 1 (magnified 10 diam.); here the nasal labyrinth is not shown.

The prenasal cartilage (*p.n.*) has increased in size, and has become straightened so as to lie nearly on the same line as the septum nasi (*s.n.*) and ethmoid (*eth.*); it has not yet reached the acme of its growth, but has become spatulate at its end, and now well represents its large counterpart in the Plagiostomous Fishes, namely their azygous snout-cartilage. The base of the ethmo-vomerine plate (*s.n., eth.*) gradually narrows to near the pituitary space (*p.t.s.*), where it rapidly enlarges, and has in its periphery first a pair of free plates (*a.p.*), and then a pair of continuous lobes or outgrowths (*l.g.*).

These free plates have, to me, only received an explanation after many years of work; on referring to my former paper (Plate VII. fig. 4, *a.p.*), it will be seen that in an embryo of *Struthio camelus*, the counterpart in development with this stage of the chick, the "anterior pterygoid processes" ("basipterygoids" of HUXLEY) grow directly out of the roots of the trabeculæ, in front and on each side of the pituitary space: the same thing takes place in the other Struthionidæ (*op. cit.* Plate IX.-XV.); and this state of things is also seen in the Lacertilia generally, and exceptionally in the Mammalia (for instance, *Cavia aperea**).

Collateral work has prepared me for seeing into the metamorphic modification of the skull-base of the Fowl as compared with that of the Ostrich. If the reader refer to the memoir on the "Shoulder-girdle and Sternum" (plates 16 & 17), he will see a precisely similar modification of parts that form the shoulder-arch; for, whilst the pre-coracoid of the Ostrich (plate 17. figs. 5 & 6, *p.cr.*) is continuous with the rest of

* Here let it be remarked that my description of the base of the skull will differ considerably from that given in the Ostrich-paper. I have now found that the "rostrum" is not preformed in cartilage, that the pituitary floor is never filled in by cartilage, that the basitemporals are at first splint-bones and afterwards ectosteal plates, that, therefore, they do not perfectly correspond with the symmetrical basisphenoids of the Lizard, and, lastly, that, notwithstanding the different modes in which they receive ossific matter, the "basipterygoid" processes of the Lizard, the Ostrich, and the Cavy are all true representatives of each other.

the shoulder-plate, in the Pheasant (plate 16. fig. 4, *p.cr.*) it is a distinct segment, later and feebler in its chondrification than the main bar. All Birds above the Ostriches agree in this; whilst all the typical Struthionidæ have a Reptilian continuity in these parts: in this they agree also with certain low Mammalia, *e. g.* the Monotremata. The manner in which the simple clavicular membrane-bone grafts itself upon the detached precoracoid of the Fowl is precisely similar to the behaviour of the splints of the skull-base of the same and other birds. Like the precoracoidal segment, the basiptyergoid plates (*a.p.*) are late in their appearance, as compared with the rest of the basisphenoidal region; their further development will be described hereafter. Ultimately it will be seen that there is nothing in the adult bird to distinguish them from those of the Ostrich, their smaller size and more forward position not being of any essential importance.

In the first stage (Plate LXXXI. fig. 2, *tr.*) the roots of the trabeculæ were seen to project outwards; in the next (fig. 8, *l.g.*) a retral lobe could just be distinguished on each side of the pituitary space; now a very perfect differentiation of this part is manifest, and a pair of very notable ear-shaped processes (Plate LXXXII. figs. 1 & 3, *l.g.*) are seen projecting backwards, one on each side of the deep "sella turcica." At present these parts are entirely cartilaginous, and present a peculiar appearance; for the cells in their interior are crowded together and full of granules (Plate LXXXI. fig. 16, magnified 250 diam.), so as to present the appearance of a very dark pith: this is similar to what is seen in the persistent trabecular rods of the Ophidia. The remarkable ornithic modification which these parts undergo will be described by and by; at present I make bold to assert that they answer to the unossified "lingulæ sphenoidales" of the human embryo: they receive their osseous deposit from another source, namely from the azygous parasphenoidal piece*; but to interpret the primordial skeleton by the after-deposits of bone is to study the *mask*, and not the *face*.

Behind the pituitary space the base of the skull, in its thick part, forms a very narrow waist; and the moieties of this pinched part are also contracted at their inner edge. This lateral retreat of the fore part of the "investing mass" gives rise to RATHKE'S "posterior basicranial fontanelle" (*p.b.f.*); it is occupied along its mid line by the notochord (Plate LXXXII. figs. 1 & 3, *n.c.*): it is not, as I once supposed, the hinder part of the original hypophysial or pituitary space, cut off by the formation of the "posterior clinoid wall," but it is a subsequent modification, caused by the opening-up and widening of the primordial fissure in which the notochord lies; for the moieties of the investing mass are seen to press closely on the notochord in the first stage (Plate LXXXI. fig. 2); the chink is larger in the second stage (fig. 8); and by the end of the second week a wide lozenge-shaped space is formed (Plate LXXXIII. fig. 2, *p.b.f.*).

Gradually, as the skull outgrows the notochord, this region becomes the shelving postpituitary part of the basisphenoid.

The thin part on each side of the fontanelle is the root of the alisphenoid (*a.s.*)—

* From a careful comparison of these parts in the lower Mammalia with those of Man, I feel satisfied that the bony "lingulæ" in that Class answer to the "basitemporal" rudiments of the "parasphenoid."

which is a crest of cartilage altogether continuous with the investing mass, and the root of the corresponding trabecula: this part will be better shown in the description of the fourth stage. On each side, and a little behind the posterior fontanelle, the investing mass rises into an elegant mammillary swelling; this is seen both above and below, and arises from the enclosed cochlea, the cavity of which, and the lower otoconial deposit, can be well seen when the skull is viewed by transmitted light (see Plate LXXXII. figs. 1 & 3, *c.l.*). These swellings reach to within a small distance of the notochord (*n.c.*); on the outside they are bounded, on the lower face of the skull, by the carotid groove (*c.g.*), and posteriorly they nearly reach to the foramen for the vagus nerve (8). The notochord (*n.c.*), which lies *above* as well as between the moieties of the investing mass, has *relatively* receded, through the more rapid growth of the surrounding structures; it is now at its fullest development, and osseous tissue has appeared on its upper surface, behind. Although belonging, in the early embryo, to the basioccipital region only, the notochord becomes constricted in several places (Plate LXXXII. fig. 3, *n.c.*) as if it were ready, if the investing mass were so disposed, to undergo hourglass-like segmentation.

The cells of which the swollen parts are composed are oval, thin-walled, and contain many granules (Plate LXXXII. fig. 5, 250 diam.); they form a good instance of cellular or indifferent tissue, as the intercellular substance is almost inappreciable. The osseous deposit takes place at first on the posterior third, on the upper face of the rod (fig. 3), and it appears as a fenestrate ectosteal plate (fig. 6, *n.c.*, 250 diam.): when once set up, the parent cells below soon disappear; and after a while the bony substance spreads over the investing mass (*i.v.*) on each side, and sets up endostosis in that part which, soon acquiring an inferior ectosteal place by the extension of ossification through the primordial chink, lays the foundation of the triple basioccipital bone.

Posteriorly another pair of smaller, but more convex mammillæ, are formed (Plate LXXXII. fig. 1, *o.c.*), these are the occipital condyles; between these, which have coalesced largely below, and in some degree above (fig. 3, *o.c.*, *n.c.*), a portion of the notochord projects, part of which belongs to the "atlas."

Outside the carotid groove the periotic portion of the investing mass becomes scooped into an oblong rounded sulcus. This sulcus has only a low wall in front, but is bounded behind by a large ear-like flap of the exoccipital lamina; this latter is the "tympanic wing of the exoccipital:" and the sulcus is the rudiment of the tympanic cavity (Plate LXXXII. fig. 1, *ty.*); at present it is filled with a soft flocculent stroma, soon to be absorbed.

The upper head of the quadrate is losing its connexion with the occipital ala at the end of the sulcus, and is acquiring a cup-and-ball articulation with the fore part.

The low ridge bounding the sulcus externally is the rudiment of the "tegmen tympani" of the Mammal; the lower lip of the tympanic cavity is supplied by the fibrous skeleton, there being no such cartilaginous lamina as is seen in the highest Class.

At present the whole of the periotic capsule is unossified; but, besides the notochordal shaft, the occipital region has acquired a pair of triangular bony patches; these are the exoccipitals (Plate LXXXII. figs. 1 & 2, *e.o.*): they extend from the posterior selvedge

to the vagus foramen; the bony matter is deposited on the inner face of the perichondrium, and soon sets up endostosis in the subjacent cells. Although commencing on the outside, the deposit soon spreads round the selvedge, along the inner face of the cartilage (Plate LXXXII. fig. 3, *e.o.*). The superoccipital lamina (Plate LXXXII. figs. 1 & 2, *s.o.*) is notched both above and below at the mid line; it is soft at present, but in a day or so acquires a small external bony patch on each side of the mid line: this is a mammalian character; and I know of only one genus (e. g. *Turdus*) in which the superoccipital is azygous. The symmetrical bony deposits seen in fig. 1 (*b.s.*) are *borrowed*, and will be described with the splint bones; the palatines (Plate LXXXII. figs. 1 & 7, *pa.*) are thoroughly ossified, and their subsequent increase is, in the Fowl, entirely at the expense of the fibrous investment, their primordial cartilaginous rod being the most transitory of any in the body; their ossification is by endostosis, the deposit commencing in the central pith of oval cells. As far as I know, this is the only instance of "primary endostosis" in the skull of the chick; in the old bird I shall describe a few endosteal patches in the nasal labyrinth*.

But the pterygoid, which is best studied at this stage, is ossified, like an ordinary shaft-bone, by "primary ectostosis" (Plate LXXXII. figs. 2 & 2B, *p.g.*), although but little of the cartilage ever becomes hyaline. The ectosteal deposit (fig. 10, *ect.*) soon spreads amongst and ossifies the cartilage-cells, which are large, extremely thin-walled, fusiform externally, and passing into almost polyhedral cells towards the interior: they contain a large granular nucleus. These simple cells are rapidly converted into bone, but much later than in the palatine bar. An ectosteal patch has appeared on the broadest part of the quadrate (fig. 2, *q.*), and an ectosteal ring on the lower branchial (Plate LXXXI. fig. 15, *c.br.*): these are all the bony deposits to be seen in the endoskeletal parts of the head at this stage.

The stapes (Plate LXXXI. fig. 14†, *st.*) has advanced very considerably in development, although entirely unossified; there can now be seen:—the wedge-shaped shaft (*st.*), the "extrastapedial" process (*e.st.*), which turns forward to apply its outer edge to the membrana tympani; the long antero-inferior process, the "infra-stapedial" (*i.st.*), which grows forward to apply itself to the lower lip of the tympanic cavity, and then becomes related to the basitemporal; and the crested postero-superior process, the "suprastapedial" (*s.st.*), to which is attached an ascending ligament. In fig. 14 the relation of the stapes to the fenestra vestibuli (*f.o.*) is shown; and in the section the squamosal (*sq.*) is seen outlying the periotic wall; then there is an open space above, which in the embryo is filled with an evanescent gelatinous tissue; mesiad of this is a section of the anterior

* The additional ossifications which appear in the palatine bar in other birds commence, in the patches that are developed into hyaline cartilage, as endostosis—as the "transpalatines" of the Passerinae, and the azygous "mesopterygoid" of *Picus viridis*. In the Fowl there is scarcely any primary endostosis in the body—merely in the carpals, tarsals, and epinenial; for, as in the "Struthionidae," their sternum is exceptionally ossified at first by ectosteal patches ('Shoulder-girdle and Sternum,' plates 16 & 17, pp. 182–191).

† The terms here used are taken from Professor HUXLEY's paper "On the Representatives of the Malleus and the Incus of the *Mammalia* in the other *Vertebrata*," Proc. Zool. Soc. 1869, pp. 391–407.

semicircular canal (*a.sc.*): the vestibule (*v.b.*) is laid open; and the back wall of the cochlea shows by transmitted light the cavity itself, and the enclosed lower otoconial mass. Mesiad of the stapes the internal carotid (*i.c.*) is seen as it runs forward to gain the open pituitary space; and the section shows also how completely continuous the periotic cartilage is with the investing mass (*i.v.*). This section is viewed from *behind*; and being somewhat oblique, the left side shows the cochlea (*c.l.*) laid quite open, and the curled plate of calcareous granules (*ot.*) is seen lying in the inner end of the sac.

The delicate distal ceratohyals (Plate LXXXI. fig. 15, *c.h.*) have coalesced at both ends, a primordial chink being left along the mid line; the basihyal (*b.h.*), basibranchial (*b.br.*), and the branchials (*c.br.*, *e.br.*) have assumed much of their persistent form.

All the membrane bones have commenced, and several of them may be described at once; the relations of the remainder will be seen best in the next stage.

The premaxillaries (Plate LXXXII. figs. 2 & 2A, *p.x.*) appear in the thick, soft, fibrous investment of the prenasal cartilage (*p.n.*) *outside* the perichondrium; they are triangular at first, and then rapidly develop their nasal (fig. 2A), marginal, and palatine processes (fig. 2),

The maxillaries* (fig. 2, *m.x.*) are developed at some distance from the endoskeleton, in the fore part of that flap which grows downwards from the maxillary rudiment (see HUXLEY, *Elem. Comp. Anat.* p. 138, fig. 57 G, *l.*); they are at first a delicate thread of fragile bone, pointed at each end, broad in the middle, and sending inwards, at their anterior third, a broad, recurved ear-shaped plate, which nearly touches the base of the septum nasi, and is the rudiment of the palatine plate or "maxillo-palatine." A much smaller style lies in the cheek-flap behind the maxillary; it is pointed at both ends, and its anterior end lies outside the end of the maxillary: this is the jugal (*j.*). Behind the jugal is the quadrato-jugal (*q.j.*); it is twice as large as the jugal, passes within it for some distance, becomes rather thick, and then curves inwards at its end to articulate with the quadrate. The nasals, frontals, parietals (not figured in the illustration of this stage) are delicate dendritic deposits in the soft fibrous tissues of the superethmoidal and cranial regions; the squamosal forms a bony eave to the prootic region (Plate LXXXI. fig. 14, *sq.*), and is formed, like the frontals and parietals, in the inner layer of the scalp, outside the perichondrium of the related cartilage.

With all these calcifying membranes every one is familiar; not so with those that substruct the base of the primordial skull.

* In the former paper (Plates VII.-XV.) the maxillaries are everywhere described as "prevomers," a term strongly inveighed against since by Professor HUXLEY. At page 113 I spoke of these as the distinct counterparts of the palatine plate of the mammalian maxillary. I shall henceforth drop the term "prevomer," and call the Lacertian bone (the so-called turbinal) "septo-maxillary;" the bone described as the maxillary in my former paper (Plate XI. fig. 1, Plate XIII. figs. 12 & 13, *mx.* p. 141) may be called the "postmaxillary" (the Fowl does not possess it). I am now satisfied that although many birds have the additional Lacertian bone truly represented by maxillary outgrowths, yet these have no existence in the Gallinacæ; and in no bird is there a distinct septo-maxillary: the counterpart of the exceptional "postmaxillary" of the Bird must be sought for far down amongst the Ganoid Fishes.

My description of these parts will differ considerably from that given in my former paper, as in my earlier observations I had mistaken the cellular tissue composing the "rostrum" for simple cartilage, and the two parosteal tracts behind it (the basitemporals) for ectosteal plates; the layer of cartilage, also, which I supposed ("Struthious Skull," p. 117) to form a floor to the pituitary space, has no existence in the Bird.

Professor HUXLEY (*op. cit.* p. 170) first showed that the so-called "basipresphenoid" of osseous Fishes is nothing but a membrane bone; in them, and in the Amphibia, a thick tract of *palato-faucial* subcutaneous fibrous tissue is converted into a large beam of bone, which runs forwards beneath the nasal region anteriorly, and backwards below the temporal region behind. This bone is well developed in the Amphibia (HUXLEY, *op. cit.* p. 214, fig. 86, B, *x*), and its posterior or temporal wings are outspread, whereas in the Fish they are often turned very sharply upwards. In the chick, in the next stage to be described, there is exactly such a tract of bone, but it has formed strong bony attachments to the true skull-base; at present this connexion has begun, but it is slight, and easily detached: but, besides this, the osseous matter is in three separate territories, instead of being one continuous sheet as in the Fish and Frog.

The anterior, narrow ossicle, the "rostrum," is styloid; it is formed by the conversion into bone of the rostral stroma figured in Plate LXXXI. figs. 6 & 7, *r.st.*; posteriorly osseous matter has run from it into the lower edge of the walls of the pituitary space; here the innermost part of a parosteal tract has become the ectosteal layer to the cartilage, and parostoses, ectostoses, and endostoses all run into each other, the first being the "cue" to the second and third: this I call the grafting of an *exoskeletal splint bone upon an endoskeletal region*.

The osseous deposit, so far forth as it has immediate relation to the cartilage of the pituitary region, forms a pair of basisphenoidal ossicles—the equivalents of the symmetrical basisphenoidals of the Lizard and of Man; these are figured as detached from the "rostrum" in Plate LXXXII. figs. 1 & 3, *b.s.*; on the upper surface (fig. 3) it is shown how the bony matter creeps round and into the trabecular root*.

The rest of the basis cranii is quite separable from the thick subcutaneous floor, and the breadth suddenly expands behind the pituitary region; so also the faucial portion of the fibrous mat is of great breadth (fig. 2, *b.t.*). In shape this layer is like the leaf of a *Bauhinia*, the "rostrum" answering to the leaf-stalk: the posterior margin of the bilobate mass is exaggerated, as to distinctness, in the figure; but in reality the web thins out rapidly in front of the exit of the vagus nerves (8): this sudden change in the thickness of the cranial floor is very remarkable, even in the adult bird.

Two large tracts of osseous deposit, the basitemporals, having a somewhat reniform outline, have already appeared in this thick fibrous web (fig. 2, *b.t.*); they are elegantly

* In certain osseous Fishes (for example the Perch, Pike, Gurnard &c.) the prepituitary portion of the basisphenoidal cartilage is invested by a delicate ectosteal sheath; this zygous basisphenoid is thus confined to the front of the pituitary space through the remarkable development of the *prootic floor*, which takes up so much of the investing mass anteriorly.

coral-like in appearance, and a row of feeble osselets lying along the grooved mid line are ready, *in a few hours*, to connect together the whole basitemporal tract. Not only do these symmetrical plates rapidly coalesce, but the "rostrum" also will have united with them by the time they have melted into each other; then the "parasphenoid" of the Ichthyopsidan will be fully represented, and the open pituitary space will be filled in below by the extraneous plate. It cannot be void of interest that the ornithic embryo is thus seen to arrive at its further goal by passing, at first, along Ichthyopsidan paths; not only is this seen in the skull-base, but also in all the outworks of the face.

The anterior termination of the "rostrum" is very thin; it lies in the midst of a large mass of stroma (Plate LXXXII. fig. 7, *r.d.s.*) underlying the perpendicular ethmoid (*eth.*), and above and between the laminar palatines (*pa.*): this section shows well how thorough the amalgamation of the trabeculæ becomes. *Conjugation* of symmetrical bands of simple cartilage at the mid line is a frequent phenomenon in the development of the skeleton.

Where the moieties of the "investing mass" embrace the pituitary body, and thus become *trabeculæ* (all the prenotochordal part of the early skull-base is trabecular), there the cartilage grows upwards into the alisphenoid (Plate LXXXII. fig. 4, *a.s.*), and downwards to form a steep wall to the pituitary space (*p.t.y.*): these walls are flanked by the "lingulæ" (*l.g.*); their nature, as outgrowths of the trabecular roots, and the dark appearance of their interior, is shown in this figure.

Fourth Stage.—Head of Embryo 10 to 12 lines long: end of 2nd, and beginning of 3rd Week of Incubation.

The primordial skull undergoes very rapid changes day by day; this will be seen at once if the figures in Plate LXXXII. are compared with those in Plate LXXXIII. All the figures in Plate LXXXIII. and figs. 8–12 in Plate LXXXII. are from a chick at the commencement of the third week of incubation, the head being an inch in length, or one-third larger than that from which the figures 1 to 7 in Plate LXXXII. are given; this stage, however, will be drawn nearer to the last by showing the structure of some younger embryos.

The basal view of the skull cannot be shown as merely primordial; so that fig. 1 in Plate LXXXIII. must be compared with figs. 1 & 2 in Plate LXXXII.: in this latter Plate the inner view of the skull-floor is only partially given, whilst in Plate LXXXIII. fig. 2 I am able to show the entire primordial skull from above, the grafted splints below not being focused.

But one of the most important changes to be noticed, and which was commencing but not described in the third stage, makes it profitable to compare the second with the fourth. We saw that in the second stage (Plate LXXXI. figs. 4 & 5) the cranio-facial axis had attained to a Struthious condition; in Plate LXXXIII. fig. 4 this part is seen to be rapidly passing into the Tinamine stage, the region common to the ethmoid and nasal septum having become largely fenestrate; this is intermediate between what is seen in

Tinamus robustus, where the "fenestra" becomes a "notch" (Struthious Skull, Plate xv. fig. 8, *c.f.c.*), and *T. variegatus*, where it has not appeared, the skull in this respect being perfectly Struthious*.

The distinction between the perpendicular ethmoid and the septum nasi is merely histological in the Mammal; but here we see a true morphological cleft, which is now imperfect above and below, and never, in the Fowl, quite complete above, although this is common in the higher arboreal types.

The vertical orbito-nasal septum has undergone fission between the eyes, as well as between the olfactory sacs: a considerable series of these clefts appear in this plate in some birds, all after one fashion; but in the Fowl there are only two, and in the Struthionidæ only one. This posterior cleft divides the ethmoid (*eth.*) from the pre-sphenoid (*p.s.*): this latter region is very feebly developed; for the fenestrate cleft ends below at a great distance from the base, and the ethmoidal and basisphenoidal regions meet below it.

The bar which encloses the anterior cleft below is very instructive; it is at present of considerable thickness (Plate LXXXIII. fig. 2, *s.v.l.*), although it is absorbed in a few days after this period. It is alate; and I propose to call the alar outgrowths the "supervomerine laminae," to connect them with their persistent and more largely developed counterparts in the Frog and the Crocodile. They have their largest development behind (see Plate LXXXII. fig. 11, which shows them magnified 20 diam., and from below); the vomer commences below the middle bar at their front end (Plate LXXXIII. fig. 1, *v.*); when there are symmetrical vomers (as in *Picus*) they commence in the fibrous tissue below the laminae. The posterior edge of the nasal septum is also alate (Plate LXXXII. fig. 4, *s.n.*), and has, in front of the alæ, an upper and a lower thickening, and a groove connecting these enlargements; this is caused by the burrowing of the nasal nerve as it passes downwards and forwards. In fig. 4 the aliethmoidal, aliseptal, and alinasal outgrowths are cut away (*al.e.*, *al.s.*, *al.n.*); the rounded and flattened prenasal cartilage (*p.n.*) is seen to have a somewhat downward direction.

The rostrum, or "anterior parasphenoid," is still quite distinct from the ethmoid, and a little also from the front of the basisphenoidal region; but directly beneath the optic nerves (2) it has grown into the substance of the cartilage, and the sella turcica is ossifying fast. The basitemporals (Plate LXXXIII. fig. 4, *b.t.*) are also rapidly coalescing with this common osseous mass, and they form a floor to the pituitary space (*pt.s.*) and also to the "posterior basicranial fontanelle" (*p.b.f.*). The notochordal shaft is now fast developing into the basioccipital bone, which still encloses the starving remains of the notochord; behind, in the unossified condyle (*o.c.*), it is still soft (figs. 1 & 4, *n.c.*).

* This cranio-facial cleft (*c.f.c.*) is a perfectly ornithic character, and in *Tinamus robustus* is a beautiful correlate of the segmentation of the shoulder-girdle across the glenoid facet and the acuteness of the angle at which the scapula and coracoid are bent upon each other. On the 9th day of incubation the scapulo-coracoid bar of the chick is falcate and partly segmented; but by the time the cranio-facial cleft is well formed (14th to 16th day) the scapula has acquired a typical condition.

An upper view of the primordial skull at this period shows much that is noteworthy (see Plate LXXXIII. fig. 2, magnified 4 diam., and with the basal parts left out of focus). The nasal labyrinth is relatively very large, and posteriorly overhangs the orbital region; it is at once seen how large and important the structures are that are trabecular in their origin; their territory ranges from the pituitary space (*p.t.s.*) behind, to the end of the prenasal cartilage (*p.n.*) in front; the postpituitary or notochordal region is short, but very broad.

In this upper view of the skull-base the basioccipital (*b.o.*) is seen to have the form of a flint spear-head: it has a longitudinal ridge arising from the enclosed notochordal shaft; its point lies between the divisions of the occipital condyle (*o.c.*), and its blunt end lies between the cochlear elevations (*c.l.*). The cartilage does not extend far beyond the cochleæ, antero-mesially, but has retired far from the mid line; this state of things, combined with the rapid growth of the investing mass and the arrest of the notochord, has caused the "posterior basicranial fontanelle" (*p.b.f.*) to become a large lozenge-shaped space, merely filled with delicate stroma.

The exoccipitals (*e.o.*) are spreading; and the superoccipitals (*s.o.*) are large, and are approaching the mid line.

The prootics (*pro.*) are rapidly developing as ectosteal plates, in front of and below the ampulla of the anterior semicircular canal (*a.s.c.*); and a large ectosteal tract covers the middle part of the alisphenoidal region. The pituitary space (*p.t.s.*) is enclosed with derived bony matter; but a considerable amount of the anterior (*a.cl.*) and posterior (*p.cl.*) clinoid walls are still soft. All the rest of the skull (its trabecular portion) is still soft, and the notochordal regions are also, to a large extent, cartilaginous. The temporal wings of the exoccipital and the postfrontal outgrowths of the alisphenoid (*p.f.*, *a.s.*) are seen to be large masses of cartilage. The foramina ovalia (5) are very large fenestral spaces between the alisphenoidal and periotic regions; and the foramina rotunda (5 *a.*) are oval in shape, and pierce the root of the "greater wing." The centre of the alisphenoid is occupied by a fenestrate cleft (*a.s.f.*); this is cordate, with the apex downwards, and tends to divide the ala into two bars—an antero-mesial and a postero-external. The alisphenoids are wide apart mesially (exaggerated in the figure), and there is no more cartilage until we reach the mid line, occupied by the knife-shaped presphenoid (*p.s.*). Thus not only is the roof of the primordial skull occupied by an enormous fontanelle, but there are two mesial fontanelles in the lowest part of the floor, and its anterior or upper division is almost entirely membranous.

The division between the two basal fontanelles (the posterior clinoid wall) is imperfect above; in my former paper (Plate VII. fig. 1, & Plate IX. fig. 1, *p.cl.*) this is shown to be perfect in the *Struthionidæ*. In the embryo of *Struthio camelus* (Plate VII. fig. 1, *o.s.*) there is also a considerable tract of cartilage underlying the fore part of the hemispheres; this is formed of the lesser wings (orbito-sphenoids): these are aborted in the Fowl*.

* The development of the sphenoidal region of the Fowl (and of *Carinate* birds generally) is thus seen to be clean contrary to what obtains in the *Lacertilia*, where the alisphenoids are absent, and the orbito-sphenoids are very large, fenestrate, and have (like the alisphenoid of the Bird) several osseous centres.

The broad roof-like frontal surface of the ethmoid (Plate LXXXIII. figs. 2, 4 & 5, *eth.*) ends in a long retral spur, which surmounts the olfactory grooves: there is no “*crista galli.*” A deep chink on each side separates the aliethmoidal (*al.e.*) from the aliseptal (*al.s.*) regions, and a lesser chink marks the posterior boundary of the alinasal (*al.n.*) region. The diverging terminations of the *alæ nasi* retain their primary form as the out-turned trabecular horns; they closely embrace that azygous outgrowth of the trabeculæ which I have called the “prenasal cartilage” (*p.n.*); this snout-cartilage is now at its full size.

In the under view (Plate LXXXIII. fig. 1) I have depicted the splints that show themselves on the basal plane, whilst the lacrymals (*l.*) and frontals (*f.*) are merely indicated by a dotted outline.

The superoccipitals (Plate LXXXII. figs. 8 & 9, *s.o.*) have nearly met above the foramen magnum (*f.m.*); the exoccipitals (*e.o.*) have enclosed the vagus (8), and are enclosing the ninth nerve (9); behind they mount over the posterior semicircular canal (*p.s.c.*), and are spreading along the tympanic wings of the occipital cartilage.

The occipital condyle (Plate LXXXII. fig. 8, and Plate LXXXIII. fig. 1, *o.c.*) has a piece of the notochord (*n.c.*) projecting from its dimpled end; in front it ends below the basioccipital, which is under-floored, anteriorly, by the huge, expanding, almost coalesced basitemporals (*b.t.*).

On each side the lower edge of the squamosal (*sq.*) is seen dipping between the post-frontal and exoccipital outgrowths.

The rostrum (Plate LXXXIII. fig. 1, *r.b.s.*) is blunt-pointed anteriorly; it lies on a somewhat higher plane than the basitemporals, and has lost its former distinctness and simplicity, having ossified much of the lower part of the basisphenoidal cartilage (*b.s.*). But not only has this centre affected the overlying cartilage, it has grown into short wings between the heads of the pterygoids, forming the roots of the “anterior pterygoid processes” (*a.p.*), and into huge *pretemporal wings* (the “posterior pterygoid processes”) (*p.r.p.*). The anterior pterygoid processes are capped with a cartilaginous plate (to be described anon), and the posterior wings have the “lingulæ sphenoidales” as their cartilaginous or endoskeletal root: this will be dilated upon when the sections are explained.

There is one more basicranial splint—the vomer (*v.*); this is a very small style, at present emarginate anteriorly, and blunt behind; but it changes its shape afterwards; it is developed in the same general tract of subcutaneous tissue as the “rostrum.” The rest of the base of the cartilaginous axis is enveloped in soft fibrous stroma, which is only subject to ossification from lateral symmetrical points.

These symmetrical ossicles are developed in the subcutaneous stroma of the facial laminae; they are the premaxillaries (*p.x.*), maxillaries (*m.x.*), jugals (*j.*), and quadrato-jugals (*q.j.*): all these have acquired considerable density since the last period. The palatines (*pa.*) are thoroughly ossified, and the pterygoids have lost most of their simple cartilaginous pith; a hyaline plate abuts against the anterior pterygoid processes, and the capped, unossified posterior end is acquiring considerable density.

The ectosteal sheath of the quadrate (*q.*) has spread largely; but the upper and lower condyles and the orbital process are still soft.

The occipito-otic region, when seen from within (Plate LXXXII. fig. 9), shows how the superoccipital bony plates spread over the posterior part of the anterior semicircular canals, and how the "prootic" ectosteal plate has begun to grow over the ampulla of the same canal.

Between the great anterior canal and the edge of the occipital plane, there is a large irregular fossa, filled now with gelatinous tissue, and afterwards with ingrowths from the parietal and squamosal. The alisphenoidal isthmus (*a.s.*), and the investing mass (*i.v.*), where it bounds the "posterior basicranial fontanelle," have been cut through. The left half of the same preparation, seen as an interno-lateral view, is shown in Plate LXXXII. fig. 10; here, besides a better view of the foramina, we see an additional proper periotic bony (ectosteal) plate—the opisthotic (*o.p.*); two more plates have yet to appear—namely, the "pterotic" and "epiotic" (mastoid).

The skull at this stage is still further illustrated by a posterior view (Plate LXXXII. fig. 8); and here the roof-bones are shown. The great upper fontanelle is being obliterated by the frontals (*f.*) and the parietals (*p.*); these are formed by an infinity of rapidly coalescing bony grains formed in the subcutaneous web: they are flanked by the squamosals (*sq.*), which have a similar nature. The two ascending occipital laminae, although they have coalesced at the mid line, yet have left traces of their original distinctness in the upper and lower notch; the superoccipitals (*s.o.*) have not yet invaded this mesial part, nor have they reached the ascending edge of the fast-growing exoccipitals (*e.o.*). Above the selvedge bounding the foramen magnum (*f.m.*) is seen the sinus canal (*s.c.*); and in the broad interspace between the super- and exoccipitals the horizontal (*h.sc.*) and posterior (*p.sc.*) semicircular canals shine out, and are seen to cross each other. Externally, and below the exoccipital region (*e.o.*), the elegant tympanic wings of the occipital cartilage form a thick crescentic selvedge. In Plate LXXXIII. fig. 4 the postorbital aspect of the skull is given; this is from a less mature specimen than that shown in figs. 1 & 2. Here, on each side above the optic nerves (2), and reaching to the olfactory crura (1), there is nothing but the laminar presphenoid, for a great extent, except membrane. This membrane is becoming bony by extension of the orbital plates of the frontals (*f.*); and infero-externally we have the alisphenoids (*a.s.*), which pass, to some extent, within the orbital plates. Much of the alisphenoidal lamina is still cartilaginous; but the *left* has an irregular ectosteal tract (*a.s.1.*) between the inner selvedge and the fenestra (*a.s.f.*). Another bony tract (*a.s.2.*) lies above the foramen ovale (5); on the right side these two plates have coalesced*. In my former paper (Plate VIII. fig. 1, p. 125) I showed that the alisphenoid (independent of its postfrontal outgrowth) had two bony centres in *Struthio* and some other birds: this appears to be the rule; but the postfrontal ossicle is not present in some of the higher (Passerine) types.

* This is a *reversed* figure.

The space between the "posterior pterygoid processes" (*p.r.p.*) and the basitemporals (*b.t.*) is filled with soft stroma, afterwards to be absorbed.

In Plate LXXXIII. fig. 5, a lateral view of the nasal labyrinth, orbital septum, and palatine is given, which shows how loose and membranous is the connexion between the ascending (orbital) plate of the palatine and the prefrontal or pars plana (*p.p.*). The continuity of this anteorbital portion of the nasal labyrinth with the upper ethmoid (*eth.*), the aliseptal (*al.s.*), and with the alinasal (*al.n.*) is clearly shown: these parts will be better understood by reference to the sectional views; and by this means we shall also come to a fuller understanding of the rest of the skull at this stage.

I shall describe the sections from before backwards; and the first of these transversely vertical sections (Plate LXXXIII. fig. 6) passes through the middle of the prenasal rod: these sectional views are magnified from 8 to 16 diameters, and are given in Plates LXXXIII. & LXXXIV.

A section through the fore part of the beak (Plate LXXXIII. fig. 6) passes through the broadest part of the prenasal cartilage, which is seen to be more convex above than below: it lies in the midst of a mass of fibrous stroma which is being rapidly converted into the solid part of the premaxillaries (*p.x.*); these are thickest above, have a cultrate edge laterally, and have, already, a small marrow cavity.

A section made a little further back (fig. 7) shows the narrower cylindrical part of the prenasal rod, and passes through the tips of the trabecular horns, or fore part of the alæ nasi (*al.n.*). Here the premaxillaries (*p.x.*) are composed of three parts—the nasal process (*n.px.*) above, the dentary margin (*d.px.*) laterally, and the palatine process (*p.px.*) on each side of the prenasal rod; the section also shows the end of the maxillary (*m.x.*).

The next section (fig. 8) has caught the fore part of the septum nasi, and has passed through the alinasal fold (*al.n.*), the lateral nasal wall (*l.n.w.*), the nasal turbinal (*n.t.b.*), the fore part of the maxillary (*m.x.*) and palatine (*pa.*), and the attenuated portions of the premaxillaries (*n.px.*, *d.px.*, *p.px.*).

Fig. 9 shows the formation of the inferior turbinals (*i.t.b.*); the section is made where the lateral nasal wall is deficient, so that the aliseptal plate turns abruptly upwards and inwards to form the inferior turbinal scroll, which has exactly two turns. The nasals (*n.*) and nasal processes of the premaxillaries surmount the labyrinth; and, leaving out other bony parts, I have shown the relation of the palatine plates of the maxillaries (maxillo-palatines, *p.mx.*) to the thick base of the the septum nasi.

The 10th figure illustrates the structure of the ethmoid behind the anteorbital plates; the ethmoidal roof (*al.e.*) is seen to be concave at the mid line, and convex laterally, the perpendicular plate (*p.e.*) to be thinnest at the middle, and the basal part to have the same bulbous outline as the septum nasi. Here, surrounded by a web of fibrous tissue, is seen the crescentic section of the "rostrum" (*r.b.s.*), and on each side the shelving section of the palatines (*pa.*) at their broadest part.

The next section (fig. 11) passes through the interorbital fenestra (*i.o.f.*). Above is seen that part of the presphenoid (*p.s.*) which runs into the perpendicular ethmoid anteriorly; it is only thickened above, and the orbito-sphenoidal regions (*o.s.*) are merely fibrous. The middle of the section is nothing but fibre—that of the fenestra; and below, the lower part of the presphenoid (*p.s.*) passes insensibly into the basisphenoid (*b.s.*). Here the “rostrum” (*r.b.s.*) is thicker, and the palatines (*pa.*) are cut through their thick but narrow pterygoid extremity. Only the lower part of the next two sections is given: in fig. 12 the soft fore end of the pterygoids (*p.g.*) is cut through, showing the enclosed cartilaginous pith; in fig. 13 the pterygoids (*p.g.*) are cut through where they interpose a cartilaginous plate between themselves and the “rostrum” (*r.b.s.*).

But the structure here indicated is better displayed in a section (fig. 14, 16 diameters) made through the basisphenoidal cartilage, exactly below the exit of the optic nerves, and immediately in front of the anterior clinoid wall. Here the section of the coalesced trabeculæ has a pyriform outline, the narrow end being upwards; this is enclosed in much fibrous tissue. Imbedded in this stroma is the rostrum (*r.b.s.*), which is here much broader, but less deep. Outside the upturned part of the rostrum there is, on each side, a plate of hyaline cartilage (*a.p.*), then a synovial cavity, then a similar plate of cartilage which is formed *in* the perichondrium of the pterygoid (*p.g.*) and *outside* its ectosteal tube.

This is very different from what obtains in the Lizard and in the Ostrich (First Paper, Plate VII. fig. 4, *a.p.*): in them the anterior pterygoid processes are direct outgrowths of the roots of the trabeculæ, and on their ends cartilage remains for articulation; in the Lizard this is very apt to acquire a rudimentary distinctness as a feebly ossified epiphysis; in both the Lizard and the Ostrich a cartilaginous plate appears on the corresponding part of the pterygoid.

Notwithstanding the different manner in which the basipterygoids of the Ostrich and the Lizard are ossified (namely, in the former from the extraneous “rostrum,” and in the latter from the symmetrical basisphenoidal ectostoses), yet, morphologically, they correspond.

This dying-out of the cartilaginous shaft of the basipterygoid outgrowth in typical birds is very instructive, being an instance of morphological subdivision in a higher type of that which is continuous (uncleft) in a lower or more generalized form.

In the Fowl the “rostrum,” insinuating itself between the basis cranii and the basipterygoid articular plate, becomes one with the true basis cranii, and, ossifying the inner face of the articular plate, leaves the rest soft for articulation with the pterygoid*.

The relation of the basitemporals to the basisphenoid is shown in section in Plate LXXXIII. fig. 4, which displays the postorbital region. In Plate LXXXIV. fig. 1, the lower portion of this section is shown, magnified 10 diameters.

This transversely vertical slice shows that the roots of the trabeculæ (*tr.*) are pyriform

* I here use, indifferently, Professor HUXLEY's term “basipterygoids,” and my older name, “anterior pterygoid processes.”

in outline (the broad part below) where they enclose the pituitary fontanelle. They are enclosed in a strong ectosteal sheath, the origin of which I showed, in Plate LXXXII. fig. 1, as being from the inner layer of the *parosteal* "rostrum;" the section is taken where the *grafting* first commenced. The bulbous base of these trabecular roots passes directly, behind, into the foremost part of the investing mass, where it encloses the posterior fontanelle (Plate LXXXII. fig. 1, *p.b.f.*), and also into the posterior clinoid wall (Plate LXXXII. fig. 3, *p.cl.*). This section well shows the absence of all cartilage under the pituitary body, and how the "sella turcica" is finished below by extraneous fibrous bone as in the Osseous Fish. The slice of cartilage seen on each side of the trabecular roots (front view) belongs proximally and below to the "lingulæ" (*l.g.*), and further outwards to the posterior clinoid wall, where it ascends into, and becomes the root of, the alisphenoidal lamina (see Plate LXXXIII. figs. 2 & 3, *al.s., p.cl.*). There is no more cartilage below the thick-edged trabeculæ; the rest of the section is entirely formed at the expense of the thick cushion of stroma which intervenes between the primordial skull and the faucial skin.

The broadening end of the "rostrum" ("anterior parasphenoid"), after forming an ectosteal plate to the roots of the trabeculæ and to the "lingulæ" (Plate LXXXII. fig. 1, *b.s., l.g.*), performs the same function for the anterior part of the posterior clinoid wall (Plate LXXXIV. fig. 1, *p.cl.*); and this it does until it reaches the lower alisphenoidal centre (Plate LXXXIII. fig. 3, *p.cl., a.s. 2*). Wholly below the cartilage, however, the bony matter, which originally commenced in a fibrous tract, breaks away again from the primordial skull, and converts large tracts of fibrous tissue into bony wings. Outside the bony deposit, shown at fig. 1, *p.cl.*, the outstretching fibrous bands become bony; below the posterior clinoid wall, a strong double pillar of bone grows down from the mid line (fig. 1); and below, transverse aponeuroses are ossified, so as, with the upper wings, to enclose a large space, which becomes the "anterior tympanic recess" (*a.t.r.*). Between the lower wings there is a central tract of bone and two open spaces; and here, at every available point, the basitemporals (*b.t.*) are forming adhesions with the wings that grow out from the basisphenoid ("posterior pterygoid processes" of former paper, or, more accurately, "tympanic wings of basisphenoid"). Laterally the lower basisphenoidal outgrowths have not united with the basitemporals; thus there is a space (*eu.*) in which the eustachian tube is formed. Between the basitemporals there is another space; this becomes the back part of the common vestibule, in which the eustachian tubes meet at the mid line.

The histology of the thick cushion of stroma which intervenes between the primordial skull and the so-called mucous membrane of the fauces is peculiar. I have spoken of the aponeurotic bands in which the bony matter runs, and must now mention that the "anterior tympanic recess" (*a.t.r.*) and the eustachian passages (*eu.*) are, at present, full of a delicate gelatino-granular stroma, of a consistence little more dense than the mucous tissue of the umbilical cord of the Mammal; this soft sarco-dal substance is soon absorbed to form the highly labyrinthine tympanic cavities.

Horizontal sections through the pituitary fontanelle throw light upon the perplexing morphology of this region of the skull*. The lowest of these (Plate LXXXIII. fig. 15) shows the internal carotids (*i.c.*) coming up from below; also the bony ring which surrounds the lower part of the pituitary body, the bony matter of which has spread right and left, ossifying a thick fibrous band (*f.*). Behind these "posterior pterygoid processes" is an open space, from which the gelatinous tissue has been removed, showing the formation of the anterior tympanic recess (*a.t.r.*); and behind this space the section passes through the lower part of the "posterior clinoid wall" (*p.cl.*), where it is growing up from the investing mass (*i.v.*). Between the moieties of this mass is seen the fore part of the "posterior basicranial fontanelle" (*p.b.f.*), which is being walled-in with bony matter. Higher up (fig. 16), above the "recess," the pituitary space is lined with a thin bony layer, which has grown up from below, whilst in front the bony substance (the same as seen at *p.cl.* in fig. 1) is just growing into the cloven "posterior clinoid wall." Behind this wall there is a thin layer of bony matter, which has crept up from the "posterior fontanelle" (fig. 15, *p.b.f.*).

Near the top (fig. 17) the thick cleft clinoid wall (*p.cl.*) is notched on each side, and the bony matter has risen up in front on each side of the notch.

Another transversely vertical section (Plate LXXXIV. fig. 2) shows, in a very instructive manner, the structure of the posterior sphenoid a little further back. The "posterior clinoid wall" (*p.cl.*) is seen to be connected by an isthmus above the fore part of the "posterior fontanelle" (*p.b.f.*); the bony matter of the "posterior pterygoid processes" (*p.r.p.*) touches the cartilage mesiad, and helps to roof-in the "anterior tympanic recess" (*a.t.r.*).

The moieties of the investing mass (*i.v.*) are here very steep, and they rest in depressions on the top of the thickest part of the massive basitemporals (*b.t.*). This section has been made behind the junction of the basisphenoidal outgrowths with the basitemporals, and well shows the membranous nature of the latter—the "posterior parasphenoids," the counterparts of the cross bars in the Fish and the Frog.

A section through the forwardly turned cochlear cavities (Plate LXXXIV. fig. 3, *c.l.*) shows the thickness of the periotic portion of the investing mass (*pr.c.*), and how the prootic ectosteal plate (*pro.*) is affecting this cartilage above, and the posterior pterygoid processes (*pr.p.*) are curling round it below. Below this latter plate is seen part of the "anterior tympanic recess" (*a.t.r.*), filled with gelatinous tissue. The floor is formed

* I have spent a large amount of anxious labour upon the development of the sphenoidal region in the various types of the Vertebrate skull, and should be glad to work it out independently if time allowed. I will here suggest that the condition of these parts in the Fowl's skull be compared with what is seen in the Marsupial, Edentate, and Insectivorous Mammals.

Let it be noted here that the "anterior tympanic recess" is formed of fibrous bony wings which, in the Marsupial, grow directly from the alisphenoidal centre, and in the Insectivora (*Erinaceus*) from the basisphenoids. In Man the "lingulae" evidently borrow their bony matter from the extraneous basitemporals; whilst in the Mammalia generally, although these splints are present, yet, as a rule, the lingulae are ossified directly from the basisphenoid.

by the lower tympanic lip of the basitemporal (*b.t.*), which further inwards underlies the cochlear cavity (*c.l.*), and at the mid line makes a secondary floor to the large open chink in the cranial floor—the “posterior basicranial fontanelle” (*p.b.f.*). The cochlear otoconial deposit (*l.ot.*) is seen, folded upon itself, in the end of the cochlear sac.

A section made a little further backwards (Plate LXXXIV. fig. 4) shows the sudden lessening of the thickness of the investing mass (*i.v.*) behind the cochlear elevation (*c.l.*). The last section (fig. 3) was made in front of the notochord; but here we come across its fore end (*n.o.*), which is enclosed in its own ectosteal sheath; this bony deposit is seen to grow upwards and outwards into the surrounding cartilage (*i.v.*), and is especially developing itself below, where it forms the lower plate of the basioccipital (*b.o.*). We are here close behind the basitemporal, in the broadest part of the basioccipital (see Plate LXXXIII. fig. 1, *b.o.*, *b.t.*). This section and the next to be described, well show the *triple* nature of the basioccipital, and also teach how small a portion of the morphology of the skeleton is involved in the mere consideration of the form and number of the separate bones.

The next section (Plate LXXXIV. fig. 5) is made where the skull-floor is thinnest—namely, just a little in front of the occipital condyle (see Plate LXXXIII. fig. 1, *b.o.*, *o.c.*). External to the basioccipital bony centre (*b.o.*) with the enclosed notochord (*n.c.*), the cartilaginous investing mass (*i.v.*) first becomes thicker and then thins out again; here it becomes enclosed within an upper and a lower ectosteal plate—the exoccipital (*e.o.*): this is more clearly shown in a more enlarged figure of this part of the section, given in Plate LXXXII. fig. 12.

The rest of the section passes through the otic region (Plate LXXXIV. fig. 5), and shows the inner wall, imperfect below (*pr.c.*), the vestibular or upper otoconial mass (*u.ot.*), the ampulla of the anterior semicircular canal (*a.sc.*), the ampulla and arch of the horizontal canal (*h.sc.*), part of the tympanic cavity (*ty.*), and part of the squamosal (*sq.*). This bone is separated from the periotic mass by a quantity of the same kind of gelatinous tissue as that which fills the tympanic cavity. The space between the squamosal and the periotic mass is very large, because of the deep angular fossa which runs along the outside of the anterior canal: this fossa is shown in Plate LXXXII. fig. 9, and in Plate LXXXIII. fig. 2, as well as in this section; it may be called the “upper periotic fossa.”

Fifth Stage.—Head of Embryo 15 lines long; 2nd Day after Hatching.

The skull of the ripe chick (Plate LXXXIV. figs. 6–12) is interesting in many respects: it is profitable for comparison with the skull of the Fish, the Reptile, and the immature Mammal; and, looked at in its general form, it comes much closer to that of the nearest congeners of the typical Fowl than the skull of the adult bird.

The types suggested by a view of the chick's skull are the Hemipodiine, Pterocline, and Columbine outliers of the Gallinaceous Family (see Trans. Zool. Soc. vol. v. plates 34–38): the skull of the adult Fowl has receded greatly from that of its lower and

more generalized relatives on one hand, and from its higher and more specialized congeners on the other.

The period of a week has sufficed for very great changes in chondrous and fibrous tracts; and now is the best nick of time for catching the true form of many of the osseous territories, although some have already lost their distinctness, whilst others have not yet appeared. The ectosteal tracts have set up "endostosis" in the cartilage lying between their plates, so that the true endoskeletal bones are being enlarged intrinsically as well as from the immediate fibrous layers. Save in the instance of the early grafted parasphenoids, the parosteal tracts (splint bones) are still altogether free from union with the endoskeleton, whether bony or cartilaginous.

The hyaline cartilage furnishing the interspaces and headlands of the ectosteal plates has become very dense through the abundance of the cheese-like intercellular substance; it is semitransparent when thick, and, for the most part, of a lilac colour.

The splint bones are still fibrous, but are beginning to become smooth through the fresh and fresh ossification of aponeurotic layers; as a correlate of this exogenous growth, the first deposit of bony matter is beginning to be absorbed in many directions, so as to form diploë: this is most advanced in the basitemporals and squamosals.

The drawings given of the ripe skull might, with very little modification, serve as diagrams to illustrate the structure of the skull in any bird above the Struthionidæ; with the "Præcoces" they answer as to *period*; but they correspond to nestlings of the "Altrices" at about the end of the first week after hatching.

The increased development of the occipital region is shown in Plate LXXXIV. figs. 6-10. The basioccipital (figs. 6 & 10, *b.o.*) has nearly obliterated the notochord, and the bony substance is spreading both laterally and backwards into the cartilaginous condyle; anteriorly (fig. 10) it has obliterated the spheno-occipital synchondrosis at the mid line. The form of the basioccipital is reptilian (lozenge-shaped) above (fig. 10), and mammalian (almost oblong) below (fig. 6).

The exoccipitals (*e.o.*) are growing into large wings, which reach up to the mastoid (epiotic) region externally and above, and approach the superoccipitals at the foramen magnum (fig. 9); inside (fig. 7) they are still quite distinct from the opisthotic (*op.*); and both outside (fig. 8) and inside (fig. 10) they have enclosed the anterior and posterior condyloid foramen (9) and the vagus-foramen (8). On the outer occipital plane (fig. 9), the exoccipitals trespass extensively upon the mastoid portion of the periotic cartilage (fig. 9, *h.sc.*, *p.sc.*); the true mastoid (epiotic) has not yet appeared.

The superoccipitals (fig. 4, *s.o.*) are fused together in their lower two-thirds, and form now a large shield of bone; internally (fig. 7) they enclose the whole crown of the huge anterior semicircular canal (*a.s.c.*) and the sinus canal (*s.c.*), which burrows along the outer face of the arch and escapes near the inferior angle (figs. 7 & 9).

The three periotic ectosteal plates which have at present made their appearance are all *inside* the cranial cavity (fig. 7). These are the front (prootic, *pro.*), the hinder (opisthotic, *op.*), and the small representative of the great otic wing of the osseous Fish

(the pterotic, *pt.o.*); this latter bone can now be seen in the "lateral cerebellar fossa," on its front face*.

A deep fossa partly subdivides the periotic mass from the occipital ring on the inside (fig. 3, *op., e.o.*); but the osseous centres are here not quite accurate landmarks of morphological regions, as the four periotic bones fail to wall-in the *upper, outer,* and *lower* portions of the auditory labyrinth: this is a reptilian state of things.

The prootic (*pro.*) is the earliest and, as a correlate of this, by far the most potent osseous growth of the four. The crested fore edge of the periotic mass helps, in front of and above the labyrinth, to enclose the cerebral mass; but the *lateness* of the small pterotic allows this cranial wing, both in the Bird and in the Mammal (see HUXLEY, *op. cit.* p. 245, fig. 97, *Pr.O.*, which shows this part in the skull of a Beaver), to be ossified by the early prootic; whereas in the Osseous Fishes the massive cranial wall is very greatly indebted to the pterotic, which is in them the largest of the periotic bones. The prootic of the Fowl (Plate LXXXIV. fig. 7, *pro.*), besides the scooped anterior crest, the front of which is notched for the trigeminal nerve (5), forms a large, backwardly turned, oblong plate, pierced along its middle for the compound seventh nerve. It is bifurcate above, where it creeps over the inside of the ampulla of the anterior canal, and also passes, in its posterior fork, to the other end of the arch; here it encloses the ovoidal pterotic plate (*p.t.o.*). The opisthotic (fig. 7, *op.*) is now a semielliptical wedge of bone, with its straight margin separated by a very narrow line of cartilage from the prootic, and its crescentic margin lying as a bank in front of the occipito-otic fossa; the line of separation between the opisthotic and the exoccipital (*e.o.*) is a very narrow band of cartilage.

The complex basisphenoidal region has now only one osseous centre, which, mace-rated away from the rest of the cranium, forms a most perplexing bone to one who has not followed its earlier history. Seen from below (Plate LXXXIV. fig. 6), we have its rostrum (*r.b.s.*), its great posterior wings (*pr.p.*), and its basitemporal floor (*b.t.*). Towards the end of the rostrum the low anterior pterygoid processes (*a.p.*) look downwards and forwards, and are covered with a meniscoid plate of cartilage. Behind them, at the mid line, the eustachian tubes open into one common vestibule, floored by the tips of the coalesced basitemporals. A notch, filled with tense membrane, is seen between the great upper wings and the basitemporals—these parts, in their meeting, not forming

* This fourth periotic bone (the so-called "mastoid," in the Fish, of CUVIER and OWEN) was first determined by me, in a note to Professor HUXLEY, who spoke very cautiously about it at first (see his 'Elem. Comp. Anat.' p. 188). In my former paper I described this bone (which is very common in the Bird-class) as the epiotic (see Plates XI.-XIII., *ep.*); but it is too far forward for that bone; the true "epiotic" (see First Paper, Plate VIII. figs. 4 & 8, *op.*) is formed over the crown of the posterior semicircular canal. My error of taking the little pterotic for the epiotic misled me in naming the latter, which I supposed to be an *outer ectosteal plate* to the opisthotic element; and in the First Paper it will be seen that the letters *op.* indicate both a postero-internal (true opisthotic) and a supero-external (true mastoid or epiotic) patch of bone. I am indebted to Professor HUXLEY for leading me to see which was the true epiotic; then the pterotic unconsciously assumed its true name.

a perfect floor to the "anterior tympanic recess." The basitemporal plate is notched on each side, where it forms a floor to the tympanic cavity, and all along its posterior margin, where it partly underlies the basioccipital (*b.o.*).

The side view (fig. 8) shows the high prepituitary part of the basisphenoid (*b.o.*) below the optic nerve (2), the rostrum (*r.b.s.*), and the tympanic lip of the basitemporal (*b.t.*).

The sectional view (fig. 7; the rostrum, *r.b.s.*, and anterior pterygoid process, *a.p.*, are not cut through) shows the rostrum, articular plate, prepituitary and postpituitary portions, the opening for the internal carotid (*i.c.*) in the fundus of the pituitary cup, and the thickness of the fast-growing basitemporals (*b.t.*) where they underlie the equally thick shelving postpituitary part of the bone; the declivity is caused by the height of the posterior clinoid wall (*p.cl.*).

The end view (fig. 9) shows how the posterior margin of the basitemporals (*b.t.*) underlies the anterior end of the basioccipital (*b.o.*) and the surrounding cartilage.

The horizontal section (fig. 10) passes through the middle of the "sella turcica," cutting away much of the anterior and posterior walls, exposing the internal carotids, showing the basisphenoidal part of the cranial floor and the obliteration of the spheno-occipital synchondrosis at the mid line. Here the posterior or tympanic wings (*p.r.p.*) are seen to be thick and cellular, and to give attachment to the fore part of the membrana tympani (*m.t.*) in the long "anterior recess;" the prootic (*pro.*) helps to wall-in this recess behind.

The pedate tract of cartilage bounded by the basisphenoid, basioccipital, and prootic contains the cochlea, which is indebted to all these bones for its outer wall. The open fontanelle (*p.b.f.*) seen at the mid line in Plate LXXXIII. fig. 2, is here filled up by the rapidly growing basisphenoid; a chink, however, remains for a long time.

The windowed alisphenoids (Plate LXXXIV. fig. 8, *a.s.*) are now well ossified, all but the outstanding "postfrontal" (*p.f.*); the suture between the alisphenoid and basisphenoid remains long distinct.

On each side a large postorbital fontanelle still exists, reaching down to the optic nerves (figs. 7 & 8, 2) below, and upwards to the frontal plate of the ethmoid (*eth.*), traversing the whole of the orbito-sphenoidal region, which is devoid of cartilage. The orbital plate of the frontal (*f.*) is gradually encroaching on this unwalled space. The whole of the presphenoid (*p.s.*) and the hinder third and lower selvedge of the perpendicular ethmoid is still unossified; but a large antero-superior tract of the latter is now ossified by a double (right and left) ectosteal plate (figs. 7 & 8, *eth.*), the cartilage within undergoing endostosis.

The lower boundary of the cranio-facial cleft (fig. 7, *c.f.c.*) has been entirely absorbed, so that the ethmoid is now merely connected by an isthmus to the postero-superior angle of the septum nasi. Through this cleft (notch) the inferior turbinal coil (*i.t.b.*) can be seen; and below this cleft the vomer (*v.*) lies, in a perfectly ornithic condition, in the base of a plate of fibrous tissue, far away from the cranio-facial axis, and ready to lay hold on the fore spurs of the palatines (fig. 6, *v., pa.*).

The nasal branch of the ophthalmic has left its burrow in the hinder part of the septum nasi, which has bridged it over both above and below.

The rather strong septum nasi (fig. 7, *s.n.*) ends in a rounded manner in front, and still retains, as a rostral process, the fast-diminishing prenasal or snout-cartilage (*p.n.*).

The swelling alinasal folds (*al.n.*), with their internal turbinal plate (*al.t.*), are best seen in fig. 8; and in it also can be seen the "pars plana" (*p.p.*), or lower part of the prefrontal plate.

The outer nasal wall (Plate LXXXIV. fig. 6, *o.n.w.*) and the prenasal bar (*p.n.*) are clearly seen from below, in the fore part of the palate.

The palatines (figs. 6 & 8, *pa.*), the pterygoids (*p.g.*), the quadrate (*q.*), and the stapes (*st.*) have all made a great approach to the adult condition. The pterygoids and palatines are well ossified; but the former have a cartilaginous cup for articulation with the quadrate, and a meniscoid plate (fig. 11, *p.g.*) for articulation with a similar disk on the anterior pterygoid process (*a.p.*, *r.b.s.*).

The meniscus which articulates the pterygoid to the basipterygoid facet is composed of typical hyaline cartilage (fig. 12, 200 diam.); this is separated from another tract of cartilage in immediate contact with the bone-cells; towards the fissure the cells are very much flattened; those in contact with the endosteal deposit are baggy simple cartilage-cells. Hence it is evident that this facet of the pterygoid is a proper segment of cartilage, and not a mere remnant of the main rod such as is seen on the quadrate end of the pterygoid.

The Fowl agrees with the Struthionidæ in having no mesopterygoid, contrary to what I once supposed (see *Zool. Trans.*, vol. v. p. 157); in the Anatine series it exists as an exogenous spur to the pterygoid; in other Carinatæ it is segmented off.

The axis of the mandible (Plate LXXXIV. figs. 7 & 8, *art.*, *m.k.*) has acquired an ectosteal ring round its internal angular process ("manubrium mallei"); all the rest is soft, and the anterior end of this cartilage has begun to shrink (fig. 7, *m.k.*); this is an anticipation of what becomes of its counterpart ("processus gracilis mallei") in the Mammal.

The stapedia shaft-bone (*st.*) is shown in figs. 8 & 10.

The ectosteal sheaths of the "basihyal" and "branchials" have advanced considerably.

Part of the fibrous skeleton has been described in connexion with the basisphenoidal "stock" on which it is grafted; the rest of the splints are easily separable from the primordial cranium.

One pair only of these have coalesced at the mid line: these are the premaxillaries (fig. 6, *p.x.*); these have already become truly Gallinaceous, although in a generalized manner they have the "habit" of those of the adults of the lower types. In figs. 6 & 7 it is shown how these bones are causing, as it were, the absorption of the axis (*p.n.*) on which they were modelled*.

* This is in conformity with what is so common in the building-up of the skull and face in the Warm-blooded Vertebrata—the "hoarding" and the "scaffolding" being formed subsequently to the proper walls and gates, which walls and gates have to be taken down to a great extent to let the hoarding and the scaffolding stand alone

The premaxillaries, anterior to their mesial coalescence, are normally ichthyic, with the exception that each bone develops a palatine process (fig. 6), as in the Mammal.

But the maxillary (figs. 6–8, *m.x.*) of the Fowl, above that of all other Birds, is ichthyic in a very remarkable manner; it is a perfect “os mystaceum;” and if the papillæ of the horny beak covering the premaxillaries may be considered (as in truth they are) to be potential teeth, then the maxillary is absolutely edentulous as in ordinary Teleostean Fishes: it is a very small, delicate style of bone, and, as in the Fish, has a double head, the anterior division articulating with the premaxillary, and the posterior with the palatine; as in the Fish, the posterior process is turned backwards.

The manner in which the Bird looks both ways (backwards to the Fish, and forwards to the Mammal) is well shown in the maxillary. In those low untypical Rodents, the Leporidae, the dentary portion of the maxillary is abortively developed in front; and the second division of the palatine part of the Fowl’s maxillary reappears in them as a narrow backwardly placed palatine plate. In most Mammals the palatine plate is truncated anteriorly to form the posterior boundary of the “anterior palatine foramen;” but in some, for instance the Pangolin (*Manis*) and the Hedgehog (*Erinaceus*), the palatine plate is sharply wedged-in anteriorly between the dentary and palatine processes of the premaxillaries, exactly as in the Fowl (Plate LXXXIV. fig. 6, *p.x., m.x.*). The retral posterior palatine plates of the Fowl’s maxillaries (maxillo-palatines of HUXLEY) are very thin, scarcely reach the vomer (*v.*), are fibrous, and are less developed than in any family except the Picinae, where they only just appear mesiad of the inner edge of the palatine (see HUXLEY “On the Classification of Birds,” Zool. Proc. 1867, pp. 448–450, figs. 30 & 31, *mxp.*).

The rest of the maxillary of the Fowl is mere style (a zygomatic process), and ends free in the upper lip, having the jugal (*j.*) mounted on and overlapping it, exactly as in those Teleostean Fishes which possess a jugal.

The jugal (Plate LXXXIV. figs. 6 & 8, *j.*) is similar in form and size to the zygomatic process of the maxillary, and is less than the quadrato-jugal (*q.j.*), which finishes the fixing-bar to the quadrate (*q.*). The quadrato-jugal, like the rest of the facial splints, continues distinct from its surroundings. The nasals (fig. 8, *n.*) overlie the frontal part of the ethmoid imperfectly, as in Struthious Birds; they have a concave semielliptic margin anteriorly; this is bounded by an upper process, which overlies the nasal process of the premaxillary, and a descending facial wall-plate, which articulates with the premaxillary and maxillary below: this lower process is a typically ornithic structure, and is aborted in the Struthionidae (see First Paper, Plates VII.–XVI., *n.*).

The lacrymal (figs. 6 & 8, *l.*) has a large superorbital and a thickish, twisted, ante-orbital plate; these two parts are distinct bones in the Lizard.

The frontals (fig. 8, *f.*) are at present very elegant shell-like bones, rounded and smooth over the cranium, hollow and scooped over the eye, and having a strong superorbital ridge. The thin dentated orbital plate only partly walls-in the orbital fontanelle (*o.f.*). The oblong, curved, four-sided parietals (figs. 7 & 8, *p.*) are overlapped behind by the

frontals (fig. 8); between the four bones, on the upper surface, is the well-known fontanelle (fig. 9, *fo.*). The posterior margin of the parietal has just reached the superoccipital (*s.o.*).

There is something very mammalian in the huge squamosals (Plate LXXXIV. figs. 6–9, *sq.*); they are, however, perfectly ornithic, having little of the Batrachian character such as is seen in the Struthionidæ; they are twice as large, relatively, as in Birds generally, and show a large square plate on the inside of the skull (fig. 7), thus supplementing the wall-plate of the prootic (*pro.*) and the alisphenoid (*a.s.*).

The squamosals of the Fowl do not show the bifurcate character so well as in the other families of Birds and of several mammalian types—for instance, *Cavia*, *Arvicola*, *Lepus*, &c. It is here (fig. 8, *sq.*) that the squamosal overlaps the whole side of the skull, over the piers of both the mandibular and the hyoid arches; thus, whilst it is the counterpart of the principal “supratemporal” of the Ganoid Fish, it extends over the region occupied by the “pteroitic:” the posterior portion of the squamosal has a separate counterpart in the Lacertilia, just as in them the descending portion of the lacrymal is separately ossified.

In the mandible, however, the splint bones are as numerous in the Bird as in the Lizard; but the Fowl is exceptional in possessing no “coronoid” piece.

The dentary (Plate LXXXIV. figs. 7 & 8, *d.*) runs backwards almost to the articular facet; the splenial (fig. 7, *sp.*) is oblong, equidistant from the ends of the ramus, and hides half the Meckelian rod.

The surangular (figs. 7 & 8, *su.*) is more external than internal; the angular (*a.*) belongs equally to both faces, being laid on below; it flanks the long posterior angular process of the endoskeletal ray.

Sixth Stage.—Chickens about 3 Weeks old.

At first sight there appeared to be but little alteration, except general advancement of the ossification, in this stage; but the specimens examined were feebly grown, and had died in a somewhat atrophied condition. They yielded two new pairs of ossific centres—the postfrontals (*p.f.*) and the epiotics (*ep.*)—which I had never before succeeded in demonstrating in the Fowl; these are shown in Plate LXXXIV. figs. 13 & 14. I am rather inclined to suppose that these bony patches were more distinct on account of the arrested growth of the chickens; at any rate, they are very instructive, and the Fowl is thus seen to agree with the Osseous Fish and with many families of its own Class in the separate formation of these bones. In my former Paper (p. 129) I stated that the postfrontal of the Bird is an ichthyic bone, the so-called postfrontal of the Lizard being a postorbital subcutaneous scale. In this, as in many other respects, it is not the Lizard but the Teleostean Fish which is the proper forerunner of the Bird.

The epiotics (fig. 13, *ep.*) are small four-sided ectosteal plates, formed over the arch of the posterior canal, and having a somewhat indistinct and very transitory separateness from the exoccipital (*e.o.*).

Seventh Stage.—Chicken 2 Months old.

In this much more advanced condition of the skull many of the sutures still remain, the two new bones described in the last stage have already lost their distinctness, and two new pairs of osseous centres have appeared.

In Plate LXXXV. fig. 1, the left half of the skull is shown from the inside, and the orbital septum, not touched by the saw, is shown on its right side; this figure is magnified 3 diameters.

Altogether the structures have begun to acquire that massiveness which characterizes the skull of the Fowl equally with that of the Ostrich. The delicately toothed sutures above, between the roof-bones, and the narrow synchondrosial tracts in the primordial skull, make this a very fitting stage for comparison with the skull of a Reptile.

The notochord is now fairly vanished from the basioccipital (*b.o.*); but the vertical dimple in the condyle is a permanent remembrancer of what once existed; the bony mass which has swallowed it up and replaced it is now a massive lozenge, capped with cartilage behind. It is surmounted on each side by the exoccipital (*e.o.*), the smooth-faced wedge-like opisthotic (*op.*), and by the postero-inferior margin of the many-sided prootic (*pro.*). Crowning all these, there is the large elegantly sculptured superoccipital (*s.o.*), half of which is occupied by the arch of the great anterior canal (*a.s.c.*), which is margined by the sinus fossa and canal (*s.c.*). The prootic (*pro.*) is seen to be connected by its wall-piece to the four-cornered alisphenoid (*a.s.*), a narrow synchondrosis uniting them; the latter has not lost its fenestra (*a.s.f.*). The pterotic (*pt.o.*) is seen in the anterior aspect of the lateral cerebellar fossa.

There is now a basisphenoid (*b.s.*) as massive as the basioccipital, and containing, between its two clinoid walls (*a.cl.*, *p.cl.*), the elegant cup-shaped cavity for the "infundibulum," pierced below for the internal carotids (*i.c.*). In front of this cup the basisphenoid forms a thick low wall, above which the optic nerves diverge. Beneath the spheno-occipital synchondrosis the thick skull-base is made doubly thick by the massive basitemporal (*b.t.*). In front of this superaddition the basal part of the equally extraneous rostrum (*r.b.s.*) is capped on each side by the basiptyergoid cartilaginous meniscus (*a.p.*).

The presphenoidal region (*p.s.*) is still soft, and the basisphenoid and perpendicular ethmoid are a long distance apart below; but along the thick upper edge of the presphenoidal cartilage there are now two pairs of bony plates—the fibrous representatives of the orbito-sphenoids.

The hinder pair evidently correspond to the ectosteal bars that appear behind the fenestra in the huge orbito-sphenoids of the Lizard; but as there are no cartilaginous "alæ minores," the ectosteal plate degenerates into a thickish "parostosis," and then grafts itself upon the indistinct orbito-sphenoidal lips of the presphenoid. The additional pair are very common in Birds; and I have mentioned the existence of two centres in the Emu in my former paper (p. 137), where they are described as part of the pre-

sphenoid; they do *cause* its ossification. The anterior bone (*o.s.*, 1) is irregularly oval; the larger posterior piece (*o.s.*, 2) is somewhat square in shape, and is fast wedged-in between the postero-superior margin of the presphenoid and the supero-anterior margin of the alisphenoid: these ossicles are still quite separable from the presphenoid, although afterwards they set up ossification in it*.

If the narrowest part of the tract of cartilage above the interorbital fenestra were quite absorbed, it would then be plainly seen what should be considered the true morphological boundaries of the perpendicular ethmoid (*p.e.*, *eth.*). This does take place in some birds, as in the Cormorant, the Sun-bittern, and the Stilt-plover; and then the cleft also runs across to the common optic foramen, so that the small presphenoid is completely severed from the ethmo-basisphenoidal band below. In the Bird the presphenoid is to be regarded as a wedge with its sharp end below, cleaving the basal region where the basisphenoid and vertical ethmoid meet: this is a remarkable modification of the Vertebrate skull. The frontal and perpendicular regions of the ethmoid are not separately ossified as in the Struthionidæ (First Paper, p. 127 *et seq.*), but the ectosteal plates (right and left) work upwards through the frontal plate. At this stage the ethmoid is an irregularly oblong plate, finished in front but deficient above, below, and behind. The notched front margin is the posterior boundary of the great craniofacial cleft. In the figure the isthmus of cartilage is seen as cut through; below, there is a small hook of cartilage, the remnant of the lower boundary of the "fenestra" of the fourth stage; this piece partly lies in the grooved fore end of the rostrum. The position, relation, and advanced development of the three great splints (*f.*, *p.*, *sq.*) that wall-in the skull are shown in Plate LXXXV. fig. 1; anteriorly the frontal is seen to retire at the mid line, thus exposing the ethmoid above.

An outer side view of this stage of the skull is shown in Plate LXXXV. fig. 2, where the superoccipital is seen to be still quite separate, and the epiotic (*ep.*) nearly coalesced with the exoccipital. In the large sulcus behind the oblique cartilaginous selvedge of the prootic (*pro.*) is seen a wedge-like plate of bone (*pt.o.*), part of which appears on the outstanding edge of the exoccipital, in front of and below the remnant of the epiotic suture. This is the pterotic, the first ectosteal plate of which appears in the front and outer part of the "lateral cerebellar fossa" (fig. 1, *pt.o.*): its subsequent development is by endostosis; at this stage it has worked to the outer surface; and here it appears *behind* the prootic (*pro.*), in *front of* and *external to* the epiotic (*ep.*), and *above* the opisthotic (*op.*).

No one familiar with the skull of the Cod, Perch, or Halibut will fail to see how

* On this ground a parostosis and an ectostosis meet, and nothing but the history of the development of the parts could have given any clue to the matter; similarly, in the Mammalia, the "cornua sphenoidalia" or mesopterygoids crop up again as mere late ossifications of membranous tracts of the pterygo-palatine arcade; and, instructively as to the case of the Bird's double orbito-sphenoids, in Man the mesopterygoids are double on each side.

true the *geographical* relations of this little bony territory are to those of the great ichthyic "pterotic" *.

The coalescence of the epiotic with the exoccipital is a Reptilian character; but there is a tendency towards that affinity of the periotic centres for each other that we see in the Mammalia, inasmuch as the prootic, pterotic, and opisthotic unite together before they coalesce with the surrounding bones. Yet this is not very perfectly maintained; for the opisthotic begins to coalesce with the exoccipital about the same time that it loses its distinctness from the prootic (see Plate LXXXV. fig. 3, *op.*, *e.o.*).

The formation of the tympanic cavity in the Bird is extremely instructive; the space itself is the remnant of the primordial cleft between the first and second poststomal arches: this stage illustrates it well.

In Plate LXXXV. fig. 2 the occipito-otic mass is seen from the outside; in fig. 3 part of the same is shown, but the skull was tilted so as to give an infero-lateral view: it is magnified one half more than fig. 2. The floor of the ear-drum, instead of being formed primarily of the inferior periotic lip, and secondarily of the tympanic bone, as in the Mammal, is here altogether formed by the basitemporal splints. This massive bone (*b.t.*) underlies the eustachian tube (fig. 1, *eu.*), the "anterior tympanic recess," and the main part of the chamber. The great wings (*p.r.p.*) that grow widely from the "lingular" bud of cartilage form a roof and side wall to the "anterior recess;" the prootic (*pro.*) forms the roof of the main chamber, and the exoccipital (*e.o.*) by its large crescentic wing forms the posterior wall. Where the prootic and exoccipital meet above the opisthotic (*op.*), there is formed a very large air-cavity—"the upper tympanic recess" (*u.t.r.*); the two ear-drums communicate with each other through the diploë that lies between these upper recesses. The outer part of the opisthotic is seen on the inner side of the drum-cavity, as an oblique bar separating the fenestra ovalis from the fenestra rotunda. Above, the opisthotic *cochlear* bar has coalesced with the exoccipital (fig. 3); below and in front it is still separate from the prootic.

The outer notched edge of the prootic (from which the squamosal has been removed) is still soft at its selvedge, and a synchondrosial tract is seen running between this bone and the crescentic wing of the exoccipital. Halfway between the outer selvedge of the prootic and the fenestra ovalis there is seen a thickened rib of bone, which passes directly forwards, and is terminated by an oblique, subconcave, oval facet; this is the point of articulation of the inner head or prootic facet of the os quadratum (Plate LXXXV. fig. 8, *q.*, *pr.f.*); the other facet of the quadrate is much larger, and articulates with the squamosal (fig. 8, *sq.f.*). This facet for the quadrate lies a little behind the great outgrowths of the basisphenoid (*pr.p.*). This articular facet marks the great difference between the Fowl's skull and that of Birds generally; for this is the primordial point of attachment, which was once lost (Plate LXXXI. figs. 1, 2, 5 & 5^a, *q.*), and then

* Professor HUXLEY would refer the epiphysis on the end of the outstanding occipito-periotic mass in the Lizard to this element, and he is undoubtedly right; the same centre keeps cropping up, in one form or another, in the Mammalia.

regained, and has become persistent. This small cup on the outside of the prootic (a large distance from the front of the exoccipital) is very similar to that for the short crus of the "incus" in the foetal Lamb. The Psittacinæ make some approach to the Fowl in the articulation of the os quadratum. It is in the Fowls—in the Common Fowl especially, and in the whole Gallo-anserine series to a great degree—that the basitemporals have their most massive development. This is correlative of the abortion of the "tympanics," which figure largely in many families of typical birds—the chief of the tympanic chain representing the "interopercular" of the Osseous Fish and the crown of the inverted arch of the tympanic ring of the Mammal. In the Fowl and in the true Gallinaceæ ("Alectoromorphæ," Huxley) I find scarcely a trace of ossification in the tendinous ring surrounding the "membrana tympani." In the Peafowl, however, a tympanic appears which is ornithically unique, although many birds have a chain of tympanics: this is formed in the posterior part of the shallow "meatus externus" (see *Memoir on Balænicæps*, p. 316), and therefore answers to the posterior part of the bony meatus of the Mammal; and lying as it does directly beneath the posterior process of the squamosal "supratemporal," it may represent the ichthyic "opercular" splint-bone*.

Eighth Stage.—Chickens 3 Months old.

The parts especially worthy of notice in this stage are the occipital, periotic, and posterior sphenoidal regions (Plate LXXXV. figs. 4–7; fig. 6 magnified 3 diameters, and the others twice the natural size).

The degree of coalescence of parts at this stage is illustrated by figures of the skull-basin. All but the parasphenoidal splints, which are so early engrafted upon the skull-base, are separable by maceration; only the symmetrical premaxillaries and dentaries have united at the mid line, the former very early, and the latter soon after hatching.

In the regions figured several of the smaller sutures are closed, and those that are still open are mostly narrow, so that the true shape of the bony territory is well shown. An upper and a lower notch still attest the original symmetry of the superoccipital (Plate LXXXV. figs. 5–7, *s.o.*). The exoccipital (*e.o.*) has completely absorbed the epiotic, which is now a mere region (*e.p.*).

The basioccipital (*b.o.*) is a thick, lozenge-shaped mass of bone, underlain by the basitemporal below (Plate LXXXV. fig. 4, *b.t.*, *b.o.*), and articulating above (fig. 5) with the basisphenoid, a notch in the mid line marking the end of the chink-like remnant of the "posterior basicranial fontanelle."

The more enlarged side view (fig. 6) should be compared with the like figure of the last stage (Plate LXXXV. fig. 2); and then it will be seen that the remnant of the epiotico-occipital suture is gone, and also the whole of that surrounding the outer part of the

* I do not wish to push this doctrine of exact representatives, or "true homologues," too far; a perfect harmony of the whole splint-category in the Vertebrata generally will be obtained when our knowledge of this wide subject is perfect,—and not till then. I may, however, mention a curious modification of the "principal tympanic" of the Crows and Singing Birds, namely, that it ennings Nitzsch's "siphonium."

pterotic (*pt.o.*); its sutures have also disappeared from the inner face of the skull. The suture between the prootic and exoccipital (*pro., e.o.*) is dying out at the middle, and on the inside only the upper part of the suture between the prootic and opisthotic remains; there is just a trace also, inside, of the suture between the exoccipital and the opisthotic. The whole para-basisphenoidal mass has long been one bone; the posterior wings (*p.r.p.*) strongly clamp the infero-anterior edge of the prootic (*pro.*), both above (fig. 5) and below (fig. 6). There are a pair of anterior clinoid spurs (fig. 5, *a.cl.*); behind these a pair of lateral spurs; and the posterior clinoid chink (fig. 5, *p.cl.*) is filled up with a mass of periosteal bone; behind this mass is the primordial chink, the remnant of the posterior fontanelle. The prepituitary part of the basisphenoid (figs. 5 & 6, *bs.*) has not nearly reached the perpendicular ethmoid; the latter part, with its surrounding cartilage, has been macerated away, leaving the rostrum (*r.b.s.*) as a long grooved style, having at its root the anterior pterygoid processes with their cartilaginous facets (*a.p.*).

The alisphenoids were still connected with the basal mass by synchondrosis, so that these do not appear in the figures.

The head of the quadrate at this stage is shown in fig. 8; the squamosal facet is a hemisphere deficient at the inner side; there is then a ligamentous line, and below this, on the inside, a somewhat reniform subconvex facet for the subconcave facet on the fore end of the rod-shaped rib of the prootic (fig. 6, *pro., q.c.*).

Ninth Stage.—Young Fowls of the 1st Winter; from 7 to 9 Months old.

The next stage may be considered to cover a period of two or three months, the specimens examined being such as were hatched in spring and killed at Christmas; here the approaches by which the adult condition is obtained are plainly shown.

A sectional view at the earlier part of this stage (Plate LXXXVI. fig. 14) displays the growing massiveness of the skull and the gradual closure of the sutures. Two extensive regions of the skull, namely the posterior sphenoid and the occipito-otic, now form one mass of bone (fig. 14, *s.o., e.o., b.o., b.t., b.s., r.b.s., pro., op.*); but the larger (*a.s.*) and lesser (*o.s.*) wings of the sphenoid are still separate. The huge perpendicular ethmoid (fig. 15, *eth.*; fig. 14, *p.e.*) now, more than ever, displays its special ornithic development. I have failed to trace any upper osseous centre such as appears in the aberrant *Struthionidæ*; but the right and left ectosteal plates, continuous in front, set up endostosis in the enclosed wall of cartilage, and spread upwards, downwards, and backwards. Here the triangular osseous patch which appears on the upper surface of the skull, between the diverging frontals (fig. 15, *eth., f.*), is not the same bone as that which shows itself in the same gap on the Ostrich's head (First Paper, Plate VIII. fig. 3, *eth.*): that is an upper ethmoid; in the Fowl it is merely a continuation of the perpendicular plate.

The bony substance spreads at the top laterally into the roots of the aliethmoids, forwards into the cranio-facial isthmus (between *eth.* and *s.n.* in fig. 14), and backwards into the retral process which overlies the olfactory grooves (1). Also below these grooves ossification is spreading into the ethmo-presphenoidal bar; in this specimen it

has reached the foremost orbito-sphenoidal patch (*o.s. 1*); towards the base it is growing towards the fore part of the basisphenoid (*b.s.*). All the rest of the cranio-facial axis is still soft; and we now see the large size of the separating cleft, through which the upper and lower turbinals (*u.tb.* and *i.tb.*) are seen. The grooves for the nasal nerve (*n.n.*) almost cut off the gnawed postero-inferior angle of the septum nasi (*s.n.*); over the lower part of each groove there is a ridge of cartilage, from which in many birds there is an outgrowth partially occluding the nostrils, and strongly cemented to the lateral splints.

The prenasal cartilage (*p.n.*) still lingers in front of the rounded fore end of the septum; after this it rapidly disappears; indeed it seldom lasts so long, this specimen being exceptional.

The splint-bones are beginning to coalesce with the endoskeletal tracts; the parietals (*p.*) and the squamosals (*sq.*) are partly fixed: the latter show a considerable surface on the inner side (Plate LXXXVI. fig. 14). All the rest of the splint-bones can be macerated away; their relations are shown from above in fig. 15, where the nasals (*n.*) are seen to have a considerable frontal portion.

The vomer (fig. 14, *v.*) is attached to the maxillo-palatine plate (*m.x.*), being widely dislocated from the base of the cranio-facial axis.

In the mandible the dentary (fig. 14, *d.*) and the splenial (*sp.*) are still separable from the fast-shrinking Meckelian rod (*m.k.*); but the angular (*a.*) and the surangular (*su.*) are partly anchylosed to the articular (*ar.*); this part, the counterpart of the bulk of the malleus, is now nearly ossified.

A more advanced skull is shown in Plate LXXXV. figs. 10 & 11, and Plate LXXXVII. fig. 1: here the free edge of the exoccipital wing (*e.o.*) and that of the postfrontal (*p.f.*) are still unossified; but the latter is now one with the alisphenoid, which is still separable from the basisphenoid (*a.s.*, *p.f.*, *b.s.*).

A narrow suture now separates the perpendicular ethmoid from the basisphenoid (Plate LXXXVII. fig. 1, *p.e.*, *b.s.*); they now meet below the still unossified part of the presphenoid (*p.s.*), which has, at last, appeared as a curved bony plate articulated by suture with the middle bar of the perpendicular ethmoid. Essentially a distinct bony patch, yet the presphenoid did not appear until the posterior orbito-sphenoid (*o.s. 2*) had affected its perichondrium; this process differs nothing from the grafting of the rostrum on the cartilage below. The alisphenoids are seen (Plate LXXXV. fig. 11) to be almost completely transverse in their position; but they overhang the postorbital space, being a continuation of the roof formed antero-superiorly by the orbital plates of the frontals (Plate LXXXVII. fig. 1, *f.*). The alisphenoidal fenestræ (Plate LXXXV. fig. 11, *a.s.f.*) are nearly filled-in by periosteal layers.

The squamosal is quite Batrachian in the Struthionidæ; it now suddenly foreshadows its counterpart in the highest Class.

I have already shown its large *inner* face (Plate LXXXVI. fig. 14, *sq.*); but its outer face is enormously expanded (compare Plate LXXXVII. fig. 1 with those in my former paper, Plates IX.-XIV.). The zygomatic process, in front of the articular facet, has not

yet appeared; but above the facet the bone spreads equally forwards and backwards, in front overlapping the postfrontal and frontal, and behind covering the upper part of the mastoid and exoccipital regions; the hinder lobe overlies the root of the hyoid arch. When the coalescing roof-bones are removed by a saw, there is displayed what is seen in Plate LXXXVII. fig. 2: anteriorly the ethmoidal ossification (*eth.*) has advanced halfway to the isthmus, and backwards along the upper and middle bars; behind the latter is seen the small presphenoid (*p.s.*), having the hinder orbito-sphenoids (*o.s.* 2) on each side; in front of these is seen the smaller pair (*o.s.* 1). The alisphenoids (*a.s.*) are attached by a fibrous band to the posterior orbito-sphenoids; the large oblique groove for the 5th nerve (5) is seen to burrow them behind.

Behind the deep perforate "sella" is still seen the primordial fissure (*p.b.f.*) or fontanelle; and at some distance behind this is the ridge formed by the notochordal shaft-bone. The saw has passed through the periotic territory, so that the whole of the horizontal semicircular canal with its ampulla (*h.s.c.*) is seen—also its connexion behind with the ascending posterior canal, the ampulla of which (*p.s.c.*) and that of the great anterior canal (*a.s.c.*) are seen lying in the same plane; outside the ampulla of the horizontal canal the upper tympanic recess (*u.t.r.*) is exposed.

The under view of a similar skull with the lower part of the basitemporal removed, is shown in Plate LXXXV. fig. 9: here the common opening of the eustachian tubes (*eu.*) is laid bare, the posterior pterygoid processes (*p.r.p.*) are cut through, and the carotid canals (*i.c.*) and cochlea (*c.l.*) are exposed. The tympanic cavity (*ty.*) is seen growing forwards into the anterior recess (*a.t.r.*), and the opening into the upper recess (*u.t.r.*) is seen behind the double quadrate condyle (*q.c.*).

Another section, more highly magnified, is shown in Plate LXXXV. fig. 8; it is an upper view, and the saw has passed through a lower plane than in Plate LXXXVII. fig. 2. Here the stapes is seen *in situ*, and the membrana tympani (*m.t.*) is seen passing over its triradiate end to be attached, anteriorly, to the great posterior pterygoid process. Behind the vestibule (*v.b.*) is seen the base of the ampulla of the posterior canal (*p.s.c.*), and a section of the lower part of its arch. Mesial of the ampulla is seen the opening for the vagus (8), and further inwards still that for the 9th (9). A bristle is figured as traversing the right drum-cavity and eustachian tube (*eu.*); and on each side of the eustachian opening the internal carotids (*i.c.*) come up. The part seen in shade, as the floor of the drum-cavity, is the basitemporal (*b.t.*).

The right stapes is shown in Plate LXXXVII. fig. 3 (6 diam.), from above, and at its base. The base is irregularly oval; the shaft, which with the base is ossified by ectostosis, is very slender; it widens, and then breaks out into a complex triradiate cartilage. The antero-inferior bar of this cartilage ("infrastapedial," *i.st.*) is slender and arcuate; the middle part ("extrastapedial," *e.st.*) is much broader and is spatulate; it curves forwards and downwards, and touches the postero-internal face of the quadrate. The postero-superior bar ("supra-stapedial," *s.st.*) is bifurcate at its free part, and from its lower edge there is a broad thin lamina which is continuous with the free end of the "extra-

stapedial," or middle process; a fenestra (*f.*) separates this oblique plate from the proximal part of the extrastapedial*.

This stage will be further illustrated by sections (principally transversely vertical, more highly magnified) (Plate LXXXVI.); these, for the most part, relate to the olfactory labyrinth, and complete what I partially described in the fourth stage (Plate LXXXIII.).

A view of the nasal labyrinth from within (fig. 10) and from above (fig. 11) will help to explain the larger sectional figures, which are magnified 4 times; the inner and upper views are one-half larger than the objects.

A section through the most swollen part of the alinasal folds (Plate LXXXVI. fig. 1) cuts through the thickest part of the nasal processes of the premaxillary (*n., px.*) and through its sharp dentary edge (*d.px.*). The styloid end of the maxillary (*mx.*) and of the palatine (*pa.*) are seen below the palatine plate of the premaxillary (*p.px.*). Here the septum nasi (*s.n.*) is deep and thin, thicker towards the top, where it spreads into the arched alinasal folds (*al.n.*); these end free opposite the middle of the septum.

Halfway from their origin the alinasals give rise to the nasal turbinal (*n.tb.*); the whole of this is seen in fig. 10, on its inner aspect. It first bends directly inwards, then passes downwards nearly parallel with the septum, and then curls outwards and upwards to its free edge.

But the nasal passage (*n.p.*) is rendered doubly valvular by a forward constriction of the cartilaginous nasal wall (*n.w.*), which (see fig. 11, *al.s., n.w.*) is continued far forwards beyond the root of the inferior turbinal, or, properly speaking, beyond the aliseptal plate. The section of this wall of the nose is here elegantly S-shaped; it ends as a thick free edge near the roof, and as a thin free edge below; and there it is only separated from the base of the septum by the nasal nerve (*n.n.*).

A little further backwards (Plate LXXXVI. figs. 2 & 11) the section passes through the alinasal (*al.n.*) where it is dying out behind; here the nasal wall (*n.w.*) is cut through obliquely, and it is seen to end (below) much further from the septum. Here the nasal turbinal (*n.tb.*) is further from the mid line, and diverges outwards to a greater extent below; this section shows the thickest part of the dentary edge of the premaxillary (*d.px.*).

The next section (fig. 3) shows a front view of the inferior turbinals (*i.tb.*); these are also seen from the inside in fig. 10; they are coiled outgrowths of the aliseptal plate (*al.s.*), which is seen to divide halfway down, giving rise to the nasal wall (*n.w.*). This section happily passes through the very important bridge for the nasal nerve (*n.n.*),

* See also Professor HUXLEY'S figures and descriptions, Proc. Zool. Soc. 1869, p. 398, figs. 5, A, B; and p. 406, fig. 8, C. These figures will be best understood by reference to what is seen in the Ouaram Lizard (*Psammisaurus*), where the bridge connecting the "extra-" and "suprastapedial" bars and the "fenestra" are absent: here the *tensor muscle*, which arises behind the "parotic bar," and above and behind the head of the quadrate, sends its tendon between the forks of the "suprastapedial"—which is bilobate as in the Fowl—to be inserted into the upper edge of the extrastapedial at its free end: the "infrastapedial" is shorter than in the Fowl. I here use these terms provisionally, as my researches into the structure of these parts in the Batrachia have satisfied me that these *prefixes* should have been set before the term "incudal."

against which the aliseptal fold terminates as a free lamina, closely tied by fibrous tissue to the nerve-bridge. Besides the proper nasal floor, we have here a true bony palatine floor; for here the palatine plates of the maxillaries (*mx.*, *p.mx.*) are at their fullest development, and are expanded where they nearly meet each other and have the vomer (*v.*) wedged in between them below. A section through this part of the skull in the Turtle (*Chelone*), in the Pangolin (*Manis*), or in the Cat (*Felis*) would show precisely the same disposition of these parts, the vomer wedging itself in between the palatine plates of the maxillaries, which fail, where the vomer crops out, to meet each other at the mid line. At this part the upper and lower crura of the nasal (*n.*) are cut through; the dentary part of the premaxillary (*d.px.*) is becoming thin, the maxillary is at its greatest breadth, and the palatine is growing thicker. The feeble, ichthyic maxillaries (*m.x.*), instead of protecting the side of the face, are seen to be almost entirely at its base.

The next section (fig. 4) is taken where the large chink is seen in the upper view (fig. 11, between *al.e.* and *al.n.*); here the aliseptal fold ends exactly where it has given off the inturned inferior turbinal coil (*i.tb.*); this coil has exactly two turns. Below, the posterior edge of the nasal wall (*n.w.*) is seen curving a little upwards where it touches the nasal nerve (*n.n.*). This section also passes through the maxillo-vomerine floor (*p.mx.*, *v.*); and here the nasal processes of the premaxillaries (*n.px.*) are flat, and the dentary processes (*d.px.*) are very small; the saw has passed through the nasals (*n.*) close in front of their bifurcation.

The next section (fig. 5) cuts through the nasals behind their bifurcation, and just takes off the fore end of the jugal (*j.*); two portions of the maxillary (*mx.*) appear in this section—namely, the zygomatic process, and the posterior edge of the palatine plate. As this section is taken behind the lateral chink, the nasal wall (*n.w.*) reappears below the inturned inferior turbinal outgrowth (*i.tb.*). The nasal nerves (*n.n.*) are seen turning downwards, and by their close contiguity they have aborted the septum nasi at this part; in many Birds, especially the Raptores, the postero-inferior angle of the septum is almost sawn off by these nerves. Another branch is seen to perforate the winged top of the septum, close below the nasal processes of the premaxillaries (*n.px.*).

In the next section (fig. 6) a front view is given of the end of the inferior turbinal (*i.tb.*), and of the anterior face of the upper turbinal (*u.tb.*); this section passes through the cranio-facial isthmus, which is still surmounted by the flat ends of the nasal processes of the premaxillaries (*n.px.*). On each side, the nasals (*n.*) form the roof-bones, which are flanked by the lacrymals (*l.*). The upper turbinal (*u.tb.*), like the lower, is seen to be an involution or outgrowth of the nasal wall (*n.w.*); and here at this point they lie one above the other; this is also shown in the lateral view in fig. 10.

In the next section (fig. 7) the inferior turbinal is cut away, and the interior of the upper turbinal (*u.tb.*) is exposed. Although appearing as a distinct outgrowth anteriorly (fig. 6, *u.tb.*), the upper turbinal is a mere bagged condition of the aliethmoidal lamina (*al.e.*) further back (see figs. 7 & 10).

A section through the fore part of the ethmoid (fig. 8, *eth.*, *p.e.*), showing the sharp front edge of the perpendicular plate, gives a front view of the back wall of the nasal labyrinth: in this figure the outer bones are not given.

This large back wall is the prefrontal plate, and much of it answers to the pars plana of anthropotomy. In this section the upper turbinal (*u.tb.*) is seen to be, at its posterior end, an outgrowth from the posterior wall of the nasal labyrinth; so that, although it is a mere swelling bag at its middle (figs. 7 & 10), yet it is a fixed outgrowth from the walls of the labyrinth at both ends. If the inner view of the left half of the cartilaginous labyrinth (fig. 10) be compared with the front view of its back wall, from which the turbinals have been cut away, leaving their roots, it will be seen that the inferior turbinal (*i.tb.*) is an outgrowth of the pars plana, posteriorly, and that its root there is continuous with that of the upper turbinal (*u.tb.*). Here there is no differentiation of a middle turbinal, except a small lamina (*m.tb.*) which grows upwards from the inner side of the root of the lower turbinal; in this respect the Gallinæ, like most other birds, are inferior to the Struthionidæ (First Paper, Plates VIII.–XIV. *m.t.b.*), which show a rudiment of those outgrowths which are so largely developed from the front face of the Mammalian "pars plana."

In this section the nasal nerves (fig. 8, *n.n.*) are seen entering the labyrinth close below the roots of the cartilaginous aliethmoid (*al.e.*); whilst the smaller olfactory crura (1) enter between the widening part of the perpendicular ethmoid (*p.e.*) and the convex margin of the crescentic root of the upper turbinal (*u.tb.*), close above a little horn-like process growing from the supero-internal angle of the pars plana (*p.p.*).

The rostrum of the basisphenoid (*r.b.s.*) reaches so far forwards as to underlie the cultrate fore edge of the perpendicular ethmoid.

A section (fig. 9) made through the most solid part of the ethmoid displays much that is instructive. The nasal processes of the premaxillaries (*n.px.*) are reduced to delicate flat styles; the nasals (*n.*) are still of considerable breadth, and overlie the wedge-like fore ends of the frontals (*f.*). The lacrymals (*l.*) send out here their broad superorbital plate, and grow downwards into an imperforate styloid anteorbital process; on the inside of each lacrymal, in the recess between this bone and the nasal labyrinth, is seen the pyriform nasal gland (*n.g.*). The huge perpendicular ethmoid (*p.e.*) has here grown out largely into the aliethmoidal wings (*al.e.*), only leaving the very edge soft, from which a narrow isthmus grows downwards, outside the nasal nerve, connecting the broad top of the ethmoid with the supero-external angle of the anteorbital (prefrontal) plate. This flat, smooth, subconvex sheet of cartilage, the anteorbital, is oblong in general form, and has sinuous edges, the inner of which, although quite distinct from, yet lies close to the perpendicular plate. In the Fowl, even to old age, it is soft; but in many birds it is ossified, and is extremely apt to form bony adhesion with the perpendicular plate. Below the anteorbitals the median plate becomes suddenly thin, swelling a little below, where it lies in the grooved rostrum (*r.b.s.*).

In this section the thick outer and the sharp orbital parts of the palatines are seen;

the latter processes lie near the rostrum, and are enveloped in the same stroma; this projecting part forms an imperfect septum between the middle nasal passages (*m.n.*), which open into each other below (compare this figure with Plate LXXXIII. fig. 10, *p.e.*, *p.a.*, *r.st.*).

The whole nasal labyrinth is continuous; the prefrontal wall, the outer wall, the turbinals, and the *alæ nasi* are all developed from that tract of the primordial skull which curls downwards, in front of the pituitary space, into the frontal wall of the embryonic skull (Plate LXXXI. figs. 1 & 2).

This free growth of cartilage into so many morphological territories is correlative to the simplicity of the tissue, which rises but a step or two beyond protoplasm, is ready to be metamorphosed into any other skeletal tissue, and yet serves as a persistent skeleton to many parts, especially those of the nasal labyrinth.

The quadrate end of the pterygoid is lined with flat-celled hyaline cartilage (Plate LXXXVI. fig. 12, *c.*), and the contiguous osseous tissue (*o.*) is formed by endosteal metamorphosis of more swollen cells.

When the cartilage-cells of the articular facet are viewed endwise (fig. 13, *c.*), they are seen to have an oval outline. The meniscoid facet has not changed, except in size, since the time of hatching.

Tenth Stage.—Fowls several years old.

By the time the young Fowl is a year old most of the cranial sutures are completely closed; and then, year by year, the skull becomes more and more dense, the periosteal layers filling-in every vacant space not needed for the transmission of vessels and nerves.

Thus in the skull of an aged bird (Plate LXXXVII. figs. 4–10) the occipital, otic, posterior and anterior sphenoidal, and the ethmoidal regions have become one continuous bone, with the old landmarks all removed, and scarcely a sign left of its once highly complex condition.

This state of things, for a bird, is quite normal; and although carried to a very high degree in the Fowl, yet in some more typical birds the obliteration of all signs of the once composite condition of the skull is still more perfect.

The present paper is linked on to the first by the description of the skull in the aberrant Struthionidæ (*Tinaminæ*, or *Dromæognathæ*); in those birds there is some falling away from what is typically struthious, and some approach to what we have here in the higher Gallinæ. In the skull, however, the Tinamous, wherein they diverge from the Ostrich-tribe, do not equally approach the Gallinæ, but rather show affinity to the Charadriomorphous types.

This, however, is not all; for the Tinamous have a tincture of the Reptilian nature in them; and whilst the sutures close very perfectly in the Ostrich, as in the Fowl and other typical birds, in them several of the most important of those landmarks remain throughout life (see First Paper, pp. 174–178, Plate xv.).

In the side view* of the skull of an old male (Plate LXXXVII. fig. 1) we see how largely the face has gained upon the skull as compared with what had obtained in the ripe chick (Plate LXXXIV. figs. 6-9), where the face had the feebleness seen in the Sand-grouse (*Syrrhaptēs*).

A zygomatic process has grown downwards from the squamosal (Plate LXXXVII. fig. 4, *sq.*), and this has formed a bridge over the lower part of the temporal fossa by coalescence with the postfrontal (*p.f.*). The fenestræ in the posterior orbital wall are all filled up, and the olfactory opening (1) is merely large enough for the nerve, whereas it once lay in a sheet of membrane.

In Plate LXXXVII. fig. 4 a trace of the interorbital space (*i.o.s.*) still exists; but in another specimen (fig. 8) the periosteal layers of bone have completely obliterated it; in the same figure which shows the inside of the cranial cavity and the left side of the orbital septum, it is seen that the rostrum (*r.b.s.*) has completely coalesced with the base of the perpendicular ethmoid (*p.e.*), and that the upper part of the ethmoid (*eth.*) has stopped its ossification at the cranio-facial isthmus. The nasal labyrinth, which is not displayed in these figures, is but little altered since the first winter (Plate LXXXVI.); but four small endosteal patches have appeared (Plate LXXXVII. fig. 10) in front of the ethmoid (*eth.*). One of these is in the isthmus; another, close in front of it, is formed in the postero-superior margin of the septum nasi (*s.n.*); and on each side of these there is one formed in that thick bridge of cartilage which protects the upper branch of the nasal nerve (Plate LXXXVI. fig. 14, *n.n.*). In the late, arrested condition of the nasal ossicles, the Fowl differs much from a large number of Birds, especially the aerial *Desmognathæ*; and many also of the *Schizognathæ* are less Reptilian in this respect than the Fowl †. The nasal bones (figs. 4 & 6, *n.*) have coalesced posteriorly with the frontals (*f.*); but the latter are wedge-like, and divergent in front, and thus expose the upper surface of the ethmoid (*eth.*): this is a Struthious character; originally, however, it answers to the skull of the Osseous Fish; it is occasionally seen in the Lizards, for instance the Iguana. The nasal processes of the premaxillaries (*n.px.*) have neither coalesced with each other, nor with the surrounding parts; the maxillæ (*mx.*), the jugals (*j.*), the quadrato-jugals (*q.j.*), and the lacrymals (*l.*) keep their distinctness to old age.

On the lower surface (Plate LXXXVII. fig. 5) the palatines (*pa.*) maintain their separateness from the palatine plates of the premaxillaries (*p.*), and also from those of the maxillaries (*mx.*). The small vomer (*v.*) also is merely attached to its surroundings by bands of fibrous tissue. The pterygoids (*p.g.*) are attached to the palatines by a rough sort of hinge, and to the quadrate (behind) by a shallow cup, which receives the pterygoid facet of the quadrate. This latter bone (*q.*) acquires a strong trochanter in front of its

* These figures of the skull of old Fowls are from preparations made in the usual way, namely, by destruction of the soft parts; so that the nasal labyrinth and septum are not shown: these figures are good for comparison with those given of adults of related types in my paper on the Gallinæ (*Zool. Trans.* vol. v. pls. 34-40).

† These terms are taken from Professor HUXLEY's paper "On the Classification of Birds," *Proc. Zool. Soc.* 1867, pp. 415-472.

upper head; below it is deeply notched, where it projects backwards from the mandibular facets, for the quadrato-jugal, which is curved to wind round the base of the quadrate (see Plate LXXXVII. figs. 4 & 5, *q.j.*, *q.*).

The mandibles vary considerably in individuals: in the one figured (fig. 4) there is scarcely a trace of the great fenestra seen in the Tetraonidæ (Zool. Trans. vol. v. pl. 36, fig. 9); but in others it is present. There is generally some trace of the suture between the posterior wedge of the dentary and the angular and surangular; but all the other sutures close; the dentaries ankylose with each other early, like the premaxillaries. In the hyoid arch the stapes undergoes no further change; the lesser cornua of the hyoid (Plate LXXXVII. fig. 11, *c.h.*) coalesce to form a glosso-hyal; but the tip of the coalesced cartilage continues soft, and a fontanelle is persistent between the bony part; this elegant sagittiform tongue-piece articulates with the basihyal (*b.h.*) by a synovial hinge.

The basihyal is carinate above, and behind articulates by a small synovial joint with the long, slender, proximally ossified basibranchial (*b.br.*). The branchial arch articulates below by a gliding synovial joint to the end of the basihyal; but the proximal piece, or "cerato-branchial" (*c.br.*), is articulated to the distal, or "epibranchial" (*e.br.*), by a mass of connective fibre; the proximal (lower) piece is soft above, and the upper piece at both ends.

When the outer table of the dense aged skull is removed, the semicircular canals (Plate LXXXVII. fig. 9, *a.s.c.*, *h.s.c.*, *p.s.c.*) are seen to be imbedded in a moderately delicate diploë: in the figure the outer tympanic walls are removed, and show the fenestra ovalis and fenestra rotunda (*f.o.*, *f.r.*) on the surface; a bristle is shown as passing along the tortuous canal for the internal carotid artery.

The figures, as compared with what is seen in Aërial Birds, show what every one is familiar with in the natural skull, namely the *non-typical* coarseness and strength of the whole skull and face*.

Concluding Remarks.

Having thus, with as much expedition and brevity as I have been competent to, run through the ten arbitrary but not unnatural stages in the morphological history of the Fowl's head, I would conclude by hinting at the importance of the various isomorphisms displayed by the skull and face of this one type in its stages of growth.

I have described it *upwards*, but my long and really anxious labour has been in the opposite direction; the stages were traced from that of the old bird *downwards* to that of the chick of the 4th day of incubation.

Whilst at work I seemed to myself to have been endeavouring to decipher a *palimpsest*, and one not erased and written upon again just once, but five or six times over.

Having erased, as it were, the characters of the culminating type—those of the gaudy Indian bird—I seemed to be amongst the sombre Grouse; and then, towards incubation,

* In a Jungle-fowl (*Gallus bankiva*) which I dissected for Professor HUXLEY, the skull was much more fibrous and less dense than in the tame Fowl: it was more like that of the Pheasant.

the characters of the Sand-grouse and Hemipod stood out before me. Rubbing these away, in my *downward* work the form of the Tinamou looked me in the face; then the aberrant Ostrich seemed to be described in large archaic characters; a little while, and these faded into what could just be read off as pertaining to the Sea-turtle*; whilst, underlying the whole, the Fish in its simplest Myxinoid form could be traced in morphological hieroglyphics.

I have but little used the suggestions of comparison, which have almost been burdensome at times; but other monographs must follow; and that of the Osseous Fish, which I hope to offer next, will show how gentle and gradual are the metamorphic changes by which the skull and face of a Vertebrate animal grow into harmony with the most diverse conditions and habits of life.

DESCRIPTION OF THE PLATES†.

PLATE LXXXI.

*First Stage.—Head of Embryo, from beak to occiput, 3 lines long:
4th Day of Incubation.*

Fig. 1. Under view of head. $\times 9$ diameters.

Fig. 2. Upper view of basis cranii. $\times 9$ diameters.

Second Stage.—Head 4 to $5\frac{1}{2}$ lines long: 5th to 7th Days of Incubation.

Fig. 3. Vertical section of skull and face of an embryo with head 4 lines in length. $\times 6$ diameters.

Fig. 4. Ditto, with brain removed, of an embryo with head 5 lines long. $\times 6$ diameters.

Fig. 5. Side view of same. $\times 6$ diameters.

Fig. 5A. Part of the last (auditory region). $\times 16$ diameters.

Fig. 6. Section of the same through nose and palate. $\times 12$ diameters.

Fig. 7. Part of the last section. $\times 160$ diameters.

Fig. 8. Floor of skull, from above, of a somewhat older embryo. $\times 12$ diameters.

* Professor HUXLEY suggests that it was most probably the Rhynchosaurian Lizard, and not the Sea-turtle, which appeared to me in my observations on that stage. It is well worthy of remark that what Dr. GÜNTHER (Phil. Trans. 1867, p. 599, Plate xxvi. fig. 2) has shown to be peculiar in *Hatteria* (a modern *Rhynchosaurian*), namely the articulation of the pterygoids with the vomers, is normal in the young Bird; in most of the Orders the "mesopterygoid," which is at first a mere extension forwards of the pterygoid, articulates with the corresponding vomerine fork; thus the palatines are thrust aside from each other, and from the mid line. This being the case, there is no difficulty about the separated palatines of *Hatteria* (see Dr. GÜNTHER'S note to p. 599); for separated palatines coexist with distinct palato-maxillaries in certain Birds—for instance, in *Emberiza* and *Cardinalis*.

† The *cartilage* is tinted of a lilac colour, and the *cartilage-bones* ochre-yellow; the *membrane-bones* and fibrous tracts are not coloured.

- Figs. 9 & 10. Anterior and lateral views of stapes. $\times 24$ diameters.
 Fig. 11. Part of palatal rod, from fig. 6. $\times 160$ diameters.
 Fig. 11A. Peripheral cells of the same. $\times 320$ diameters.
 Fig. 11B. Central cells of the same. $\times 320$ diameters.
 Fig. 12. Mandibles and tongue from the above. $\times 12$ diameters.
 Fig. 13. Proximal part of mandible of an embryo somewhat older. $\times 24$ diameters.

Third Stage.—Head of Embryo 8 or 9 lines long: middle of 2nd Week.

- Fig. 14. Transversely vertical section of auditory sacs. $\times 10$ diameters.
 Fig. 15. Os hyoides. $\times 4$ diameters.
 Fig. 16. Part of cartilaginous “lingula sphenoidalis.” $\times 250$ diameters.

PLATE LXXXII.

Third Stage (continued).

- Fig. 1. Basal view of skull, with outer bones removed. $\times 10$ diameters.
 Fig. 2. Ditto, with splints and palatal bones. $\times 10$ diameters.
 Fig. 2A. Part of the same, from above. $\times 10$ diameters.
 Fig. 2B. Section of pterygoid. $\times 250$ diameters.
 Fig. 3. Part of fig. 1, from above. $\times 13\frac{1}{3}$ diameters.
 Fig. 4. Transverse section of “sella turcica.” $\times 20$ diameters.
 Fig. 5. Anterior part of notochord. $\times 250$ diameters.
 Fig. 6. Posterior part of ditto. $\times 250$ diameters.
 Fig. 7. Section of orbital septum and palatines. $\times 20$ diameters.

Fourth Stage.—Head of Embryo 10 to 12 lines long: end of 2nd and beginning of 3rd Week.

- Fig. 8. End of skull; outer view. $\times 5$ diameters.
 Fig. 9. End of skull; inner view. $\times 5$ diameters.
 Fig. 10. Half of the same, from within. $\times 5$ diameters.
 Fig. 11. Alate portion of septum nasi. $\times 20$ diameters.
 Fig. 12. Transverse section through occipital region. $\times 20$ diameters.

PLATE LXXXIII.

Fourth Stage (continued).

- Fig. 1. Basal view of skull. $\times 4$ diameters.
 Fig. 2. Upper ditto, with splints removed. $\times 4$ diameters.
 Fig. 3. Front ditto, with orbital septum removed. $\times 4$ diameters.
 Fig. 4. Section of skull with lateral parts removed. $\times 4$ diameters.
 Fig. 5. Side view of orbital and nasal regions. $\times 4$ diameters.

Figs. 6–9. Sections of nasal region. $\times 8$ diameters.

Figs. 10 & 11. Sections of orbital region. $\times 10$ diameters.

Figs. 12 & 13. Section of base of interorbital region and part of pterygoids. $\times 8$ diameters.

Fig. 14. The same, below optic nerves. $\times 16$ diameters.

Figs. 15–17. Horizontal sections through “sella turcica.” $\times 8$ diameters.

PLATE LXXXIV.

Fourth Stage (continued).

Figs. 1–5. Vertical sections through skull-base. $\times 7$ & 10 diameters.

Fifth Stage.—Head 15 lines long: Chickens 2 Days old.

Fig. 6. Basal view of skull. $\times 3$ diameters.

Fig. 7. Sectional view of skull. $\times 3$ diameters.

Fig. 8. Side view of skull. $\times 3$ diameters.

Fig. 9. End view of skull. $\times 3$ diameters.

Fig. 10. Horizontal section of skull. $\times 4$ diameters.

Fig. 11. Junction of pterygoid with skull. $\times 16$ diameters.

Fig. 12. Part of pterygoid. $\times 200$ diameters.

Sixth Stage.—Chicken 3 Weeks old.

Fig. 13. End view of skull. $\times 3$ diameters.

Fig. 14. Half of front view of skull. $\times 3$ diameters.

PLATE LXXXV.

Seventh Stage.—Chicken 2 Months old.

Fig. 1. Vertical section of skull. $\times 3$ diameters.

Fig. 2. Side view of occipital region. $\times 4\frac{1}{2}$ diameters.

Fig. 3. Part of the same, seen obliquely. $\times 6$ diameters.

Eighth Stage.—Chicken 3 Months old.

Fig. 4. Basal view of skull. $\times 2$ diameters.

Fig. 5. Upper view of skull. $\times 2$ diameters.

Fig. 6. Lateral view of skull. $\times 3$ diameters.

Fig. 7. Posterior view of skull. $\times 2$ diameters.

Fig. 7A. Inner view of head of quadrate. $\times 4$ diameters.

Ninth Stage.—Fowls 7 to 9 Months old.

Fig. 8. Horizontal section of skull, from above. $\times 3$ diameters.

Fig. 9. Horizontal section of skull, from below. $\times 2$ diameters.

Fig. 10. End view of skull. $\times 2$ diameters.

Fig. 11. Front view of skull. $\times 2$ diameters.

PLATE LXXXVI.

Ninth Stage (continued).

Figs. 1-9. Sections through nasal region. $\times 4$ diameters.

Fig. 10. Vertical section of nasal region. $\times 1\frac{1}{2}$ diameter.

Fig. 11. The same region, from above. $\times 1\frac{1}{2}$ diameter.

Figs. 12 & 13. Sections of pterygoid. $\times 200$ diameters.

Fig. 14. Section of skull. $\times 1\frac{1}{2}$ diameter.

Fig. 15. Skull seen from above. $\times 1\frac{1}{2}$ diameter.

PLATE LXXXVII.

Ninth Stage (continued).

Fig. 1. Side view of skull. $\times 1\frac{1}{2}$ diameter.

Fig. 2. Horizontal section of skull, upper view. $\times 1\frac{1}{2}$ diameter.

Fig. 3. Stapes, lateral and basal views. $\times 6$ diameters.

Tenth Stage.—Old Fowls.

Fig. 4. Side view of skull. $\times 1\frac{1}{2}$ diameter.

Fig. 5. Basal view of skull. $\times 1\frac{1}{2}$ diameter.

Fig. 6. Upper view of skull. $\times 1\frac{1}{2}$ diameter.

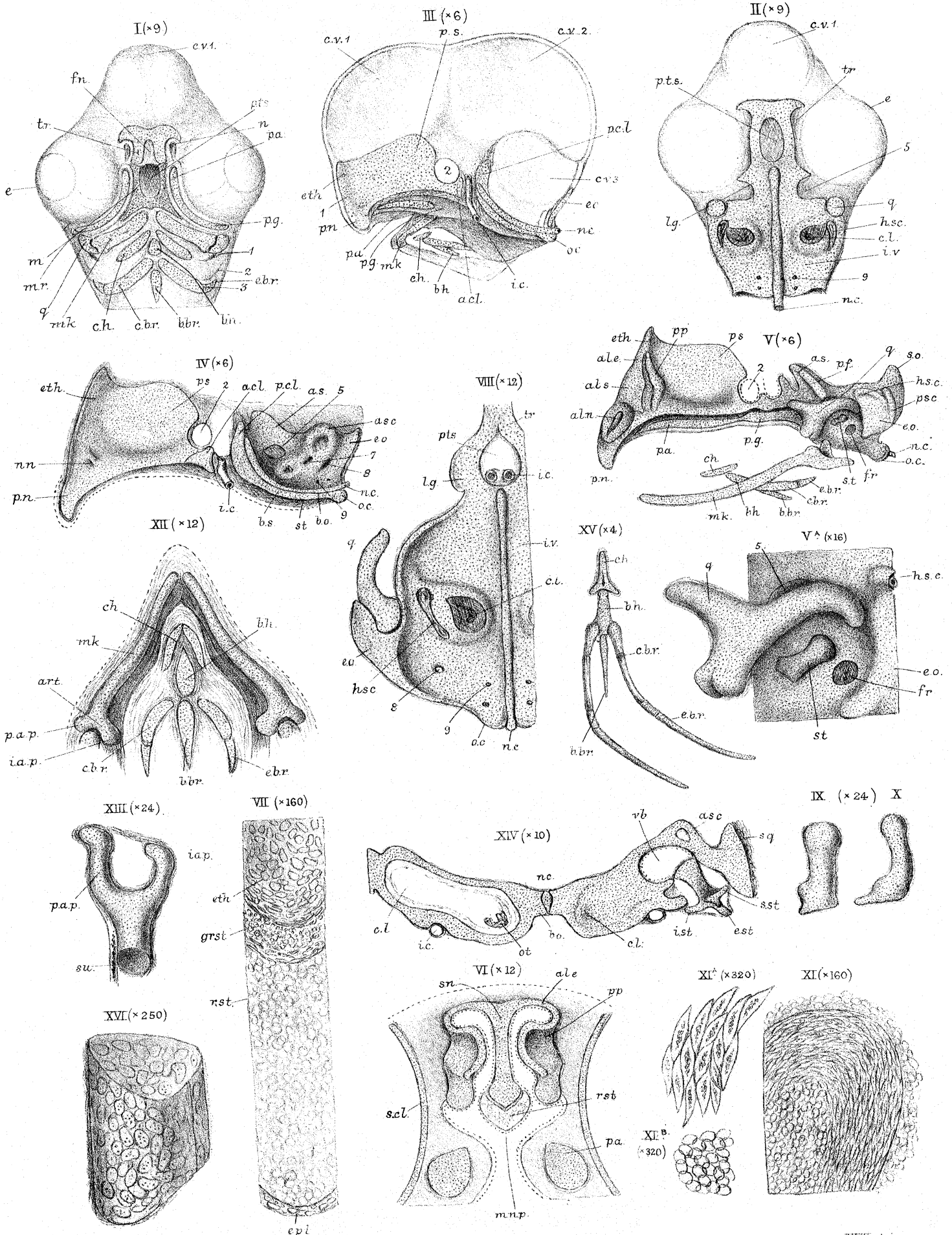
Fig. 7. Posterior view of skull. $\times 1\frac{1}{2}$ diameter.

Fig. 8. Sectional view of skull. $\times 1\frac{1}{2}$ diameter.

Fig. 9. Side view of skull with auditory structures exposed. $\times 2\frac{1}{2}$ diameters.

Fig. 10. Lower view of part of nasal septum. $\times 2$ diameters.

Fig. 11. Os hyoides. $\times 1\frac{1}{2}$ diameter.

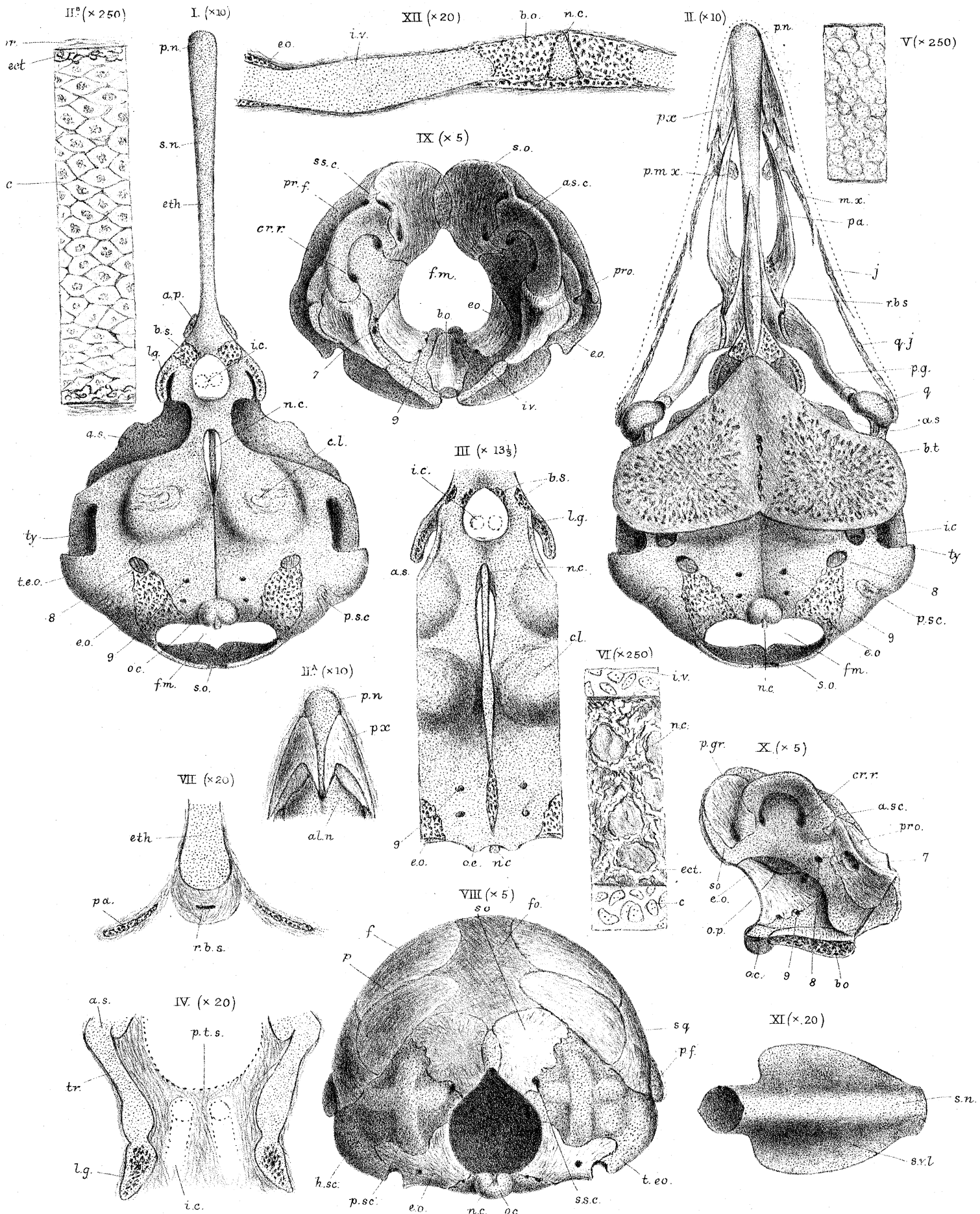


W.K.P. del ad.nat. Geo. West lith.

W.West imp.

Fowl's Skull.

Figs. I, II. 1st Stage. Figs. III - XIII. 2nd Stage. Figs. XIV - XVII. 3rd Stage.

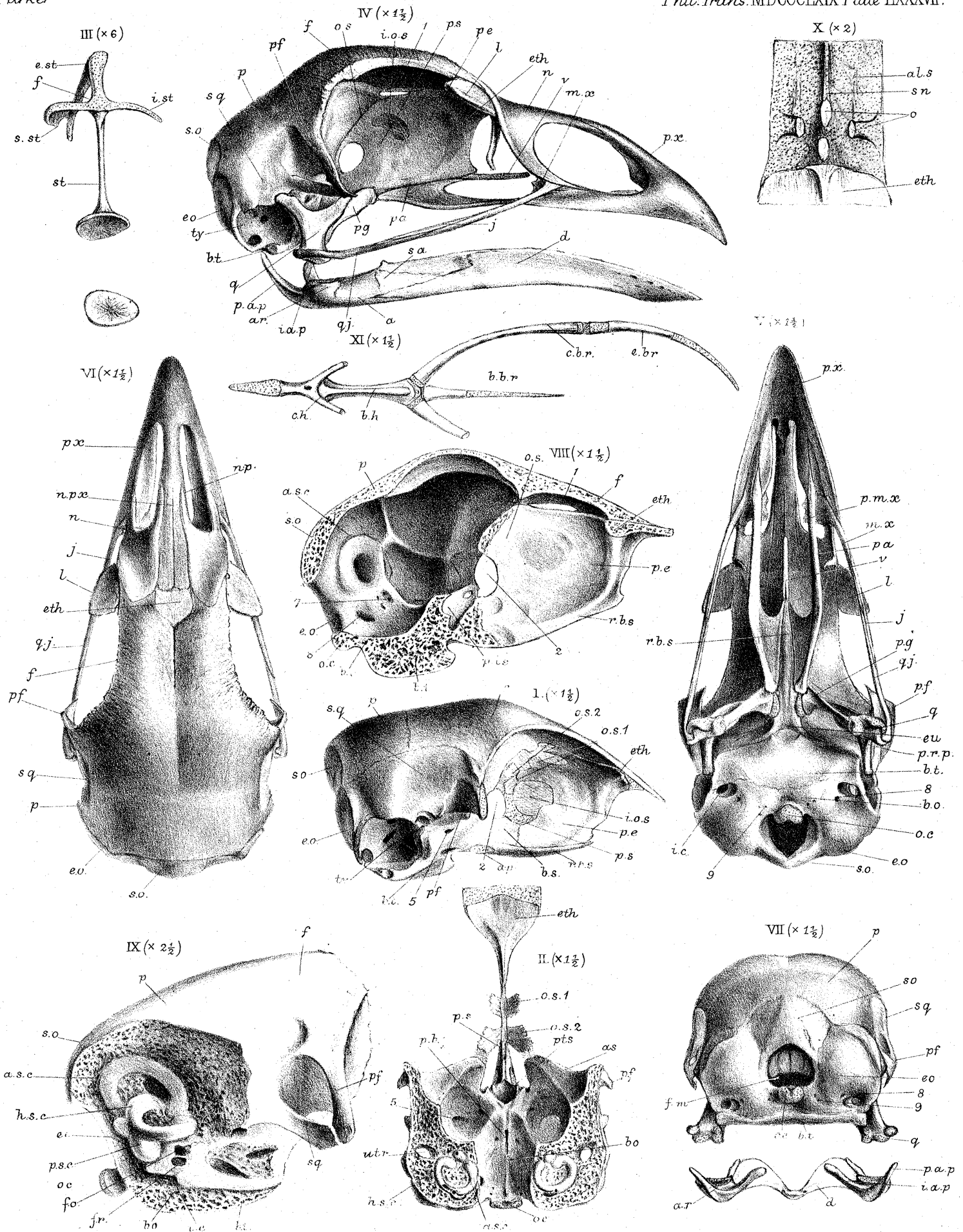


W.K.P. del ad nat, Geo. West lith.

Fowl's Skull.

W West imp

Figs. I-VII 3rd Stage. Figs. VIII-XII 4th Stage.

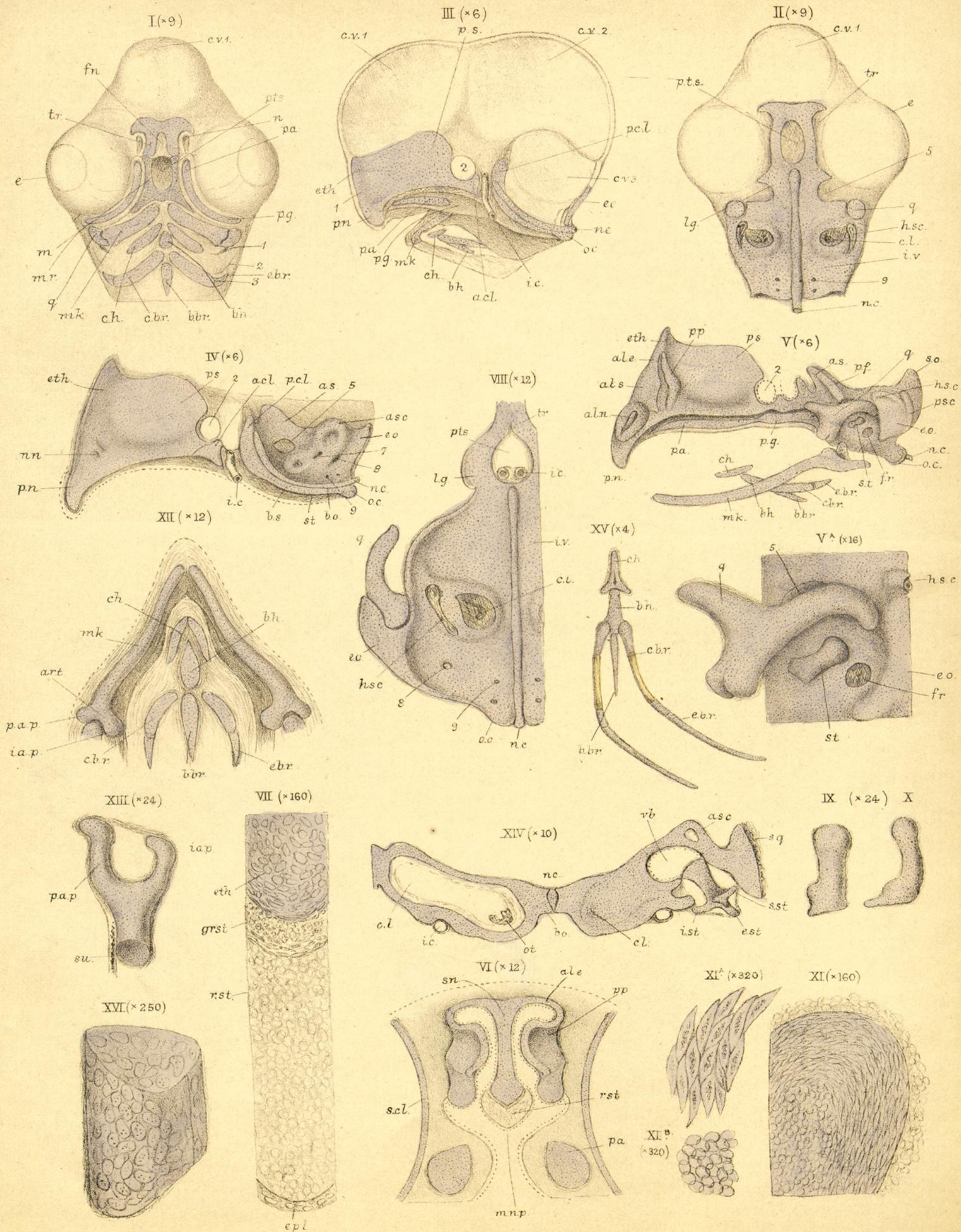


W.K.P. del. et nat. Geo. West lith.

W. West imp.

Fowl's Skull

Figs. I - III. 9th Stage cont. Figs. IV - XI. 10th Stage.



Fowl's Skull.

PLATE LXXXI.

First Stage.—Head of Embryo, from beak to occiput, 3 lines long: 4th Day of Incubation.

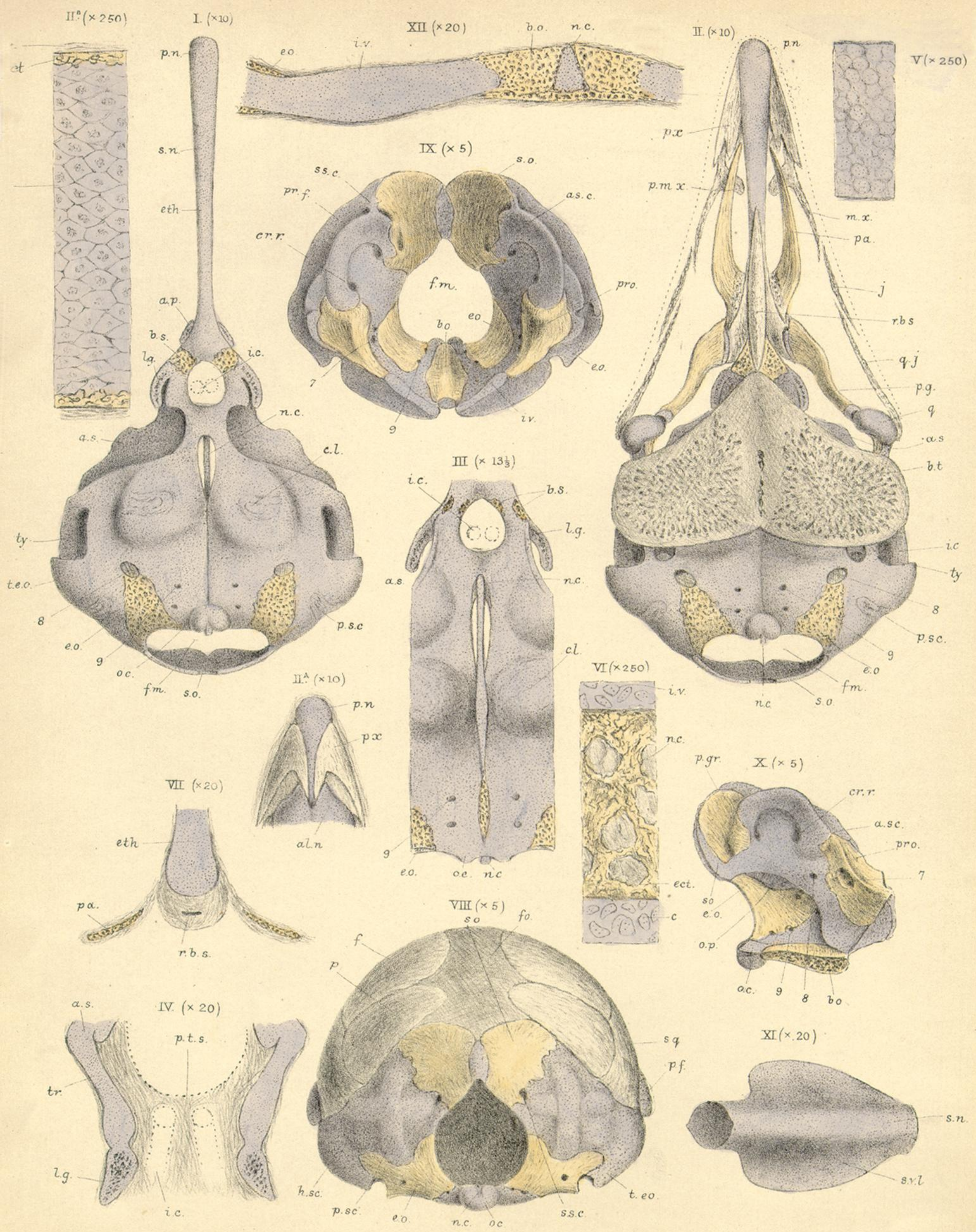
- Fig. 1. Under view of head. × 9 diameters.
- Fig. 2. Upper view of basis cranii. × 9 diameters.

Second Stage.—Head 4 to 5½ lines long: 5th to 7th Days of Incubation.

- Fig. 3. Vertical section of skull and face of an embryo with head 4 lines in length. × 6 diameters.
- Fig. 4. Ditto, with brain removed, of an embryo with head 5 lines long. × 6 diameters.
- Fig. 5. Side view of same. × 6 diameters.
- Fig. 5A. Part of the last (auditory region). × 16 diameters.
- Fig. 6. Section of the same through nose and palate. × 12 diameters.
- Fig. 7. Part of the last section. × 160 diameters.
- Fig. 8. Floor of skull, from above, of a somewhat older embryo. × 12 diameters.
- Figs. 9 & 10. Anterior and lateral views of stapes. × 24 diameters.
- Fig. 11. Part of palatal rod, from fig. 6. × 160 diameters.
- Fig. 11A. Peripheral cells of the same. × 320 diameters.
- Fig. 11B. Central cells of the same. × 320 diameters.
- Fig. 12. Mandibles and tongue from the above. × 12 diameters.
- Fig. 13. Proximal part of mandible of an embryo somewhat older. × 24 diameters.

Third Stage.—Head of Embryo 8 or 9 lines long: middle of 2nd Week.

- Fig. 14. Transversely vertical section of auditory sacs. × 10 diameters.
- Fig. 15. Os hyoides. × 4 diameters.
- Fig. 16. Part of cartilaginous "lingula sphenoidalis." × 250 diameters.



Fowl's Skull.

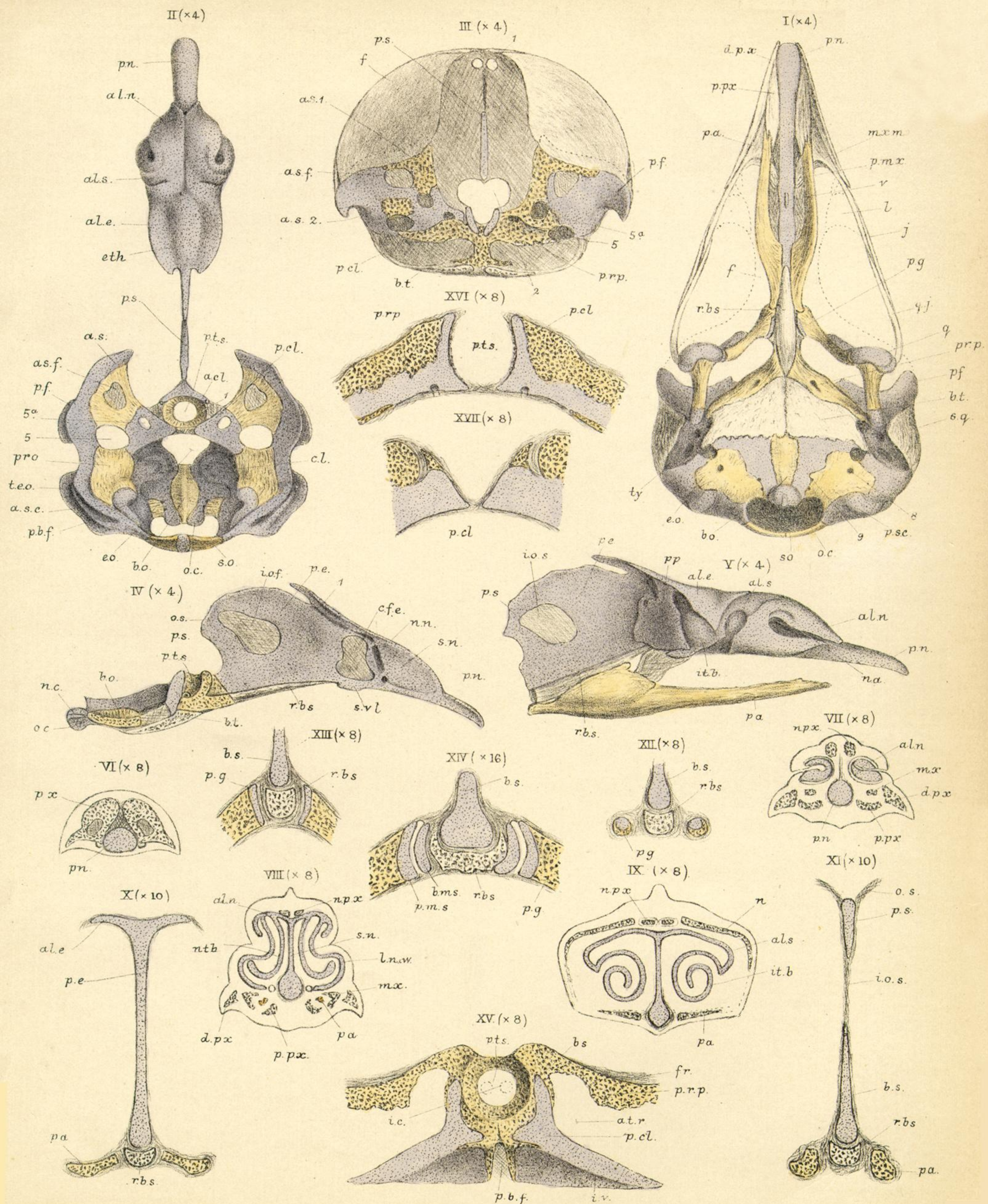
PLATE LXXXII.

Third Stage (continued).

- Fig. 1. Basal view of skull, with outer bones removed. $\times 10$ diameters.
 Fig. 2. Ditto, with splints and palatal bones. $\times 10$ diameters.
 Fig. 2A. Part of the same, from above. $\times 10$ diameters.
 Fig. 2B. Section of pterygoid. $\times 250$ diameters.
 Fig. 3. Part of fig. 1, from above. $\times 13\frac{1}{2}$ diameters.
 Fig. 4. Transverse section of "sella turcica." $\times 20$ diameters.
 Fig. 5. Anterior part of notochord. $\times 250$ diameters.
 Fig. 6. Posterior part of ditto. $\times 250$ diameters.
 Fig. 7. Section of orbital septum and palatines. $\times 20$ diameters.

Fourth Stage.—Head of Embryo 10 to 12 lines long: end of 2nd and beginning of 3rd Week.

- Fig. 8. End of skull; outer view. $\times 5$ diameters.
 Fig. 9. End of skull; inner view. $\times 5$ diameters.
 Fig. 10. Half of the same, from within. $\times 5$ diameters.
 Fig. 11. Alate portion of septum nasi. $\times 20$ diameters.
 Fig. 12. Transverse section through occipital region. $\times 20$ diameters.

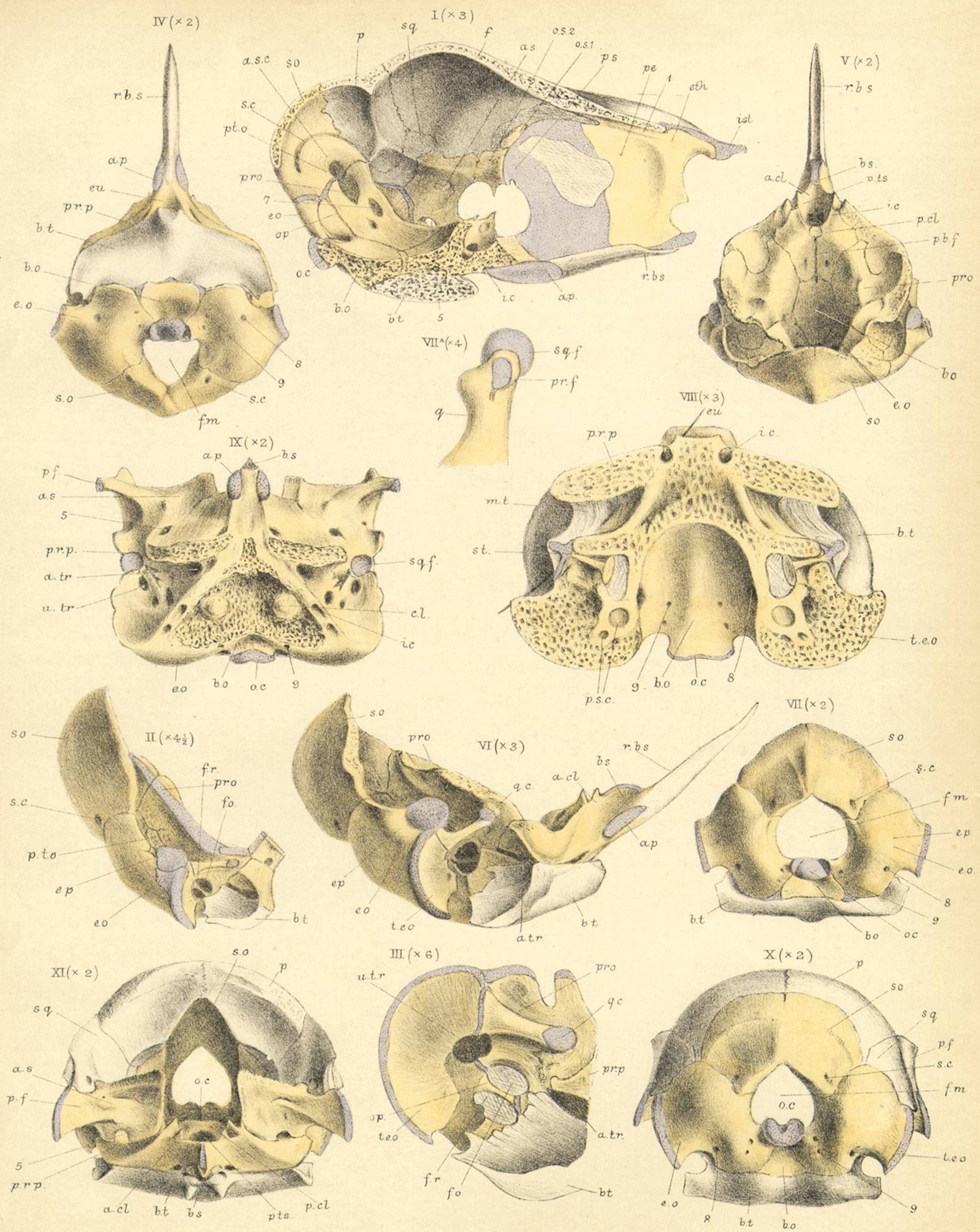


Fowl's Skull.

PLATE LXXXIII.

Fourth Stage (continued).

- Fig. 1. Basal view of skull. × 4 diameters.
- Fig. 2. Upper ditto, with splints removed. × 4 diameters.
- Fig. 3. Front ditto, with orbital septum removed. × 4 diameters.
- Fig. 4. Section of skull with lateral parts removed. × 4 diameters.
- Fig. 5. Side view of orbital and nasal regions. × 4 diameters.
- Figs. 6-9. Sections of nasal region. × 8 diameters.
- Figs. 10 & 11. Sections of orbital region. × 10 diameters.
- Figs. 12 & 13. Section of base of interorbital region and part of pterygoids. × 8 diameters.
- Fig. 14. The same, below optic nerves. × 16 diameters.
- Figs. 15-17. Horizontal sections through "sella turcica." × 8 diameters.



Fowl's Skull.
 PLATE LXXXV.

Seventh Stage.—Chicken 2 Months old.

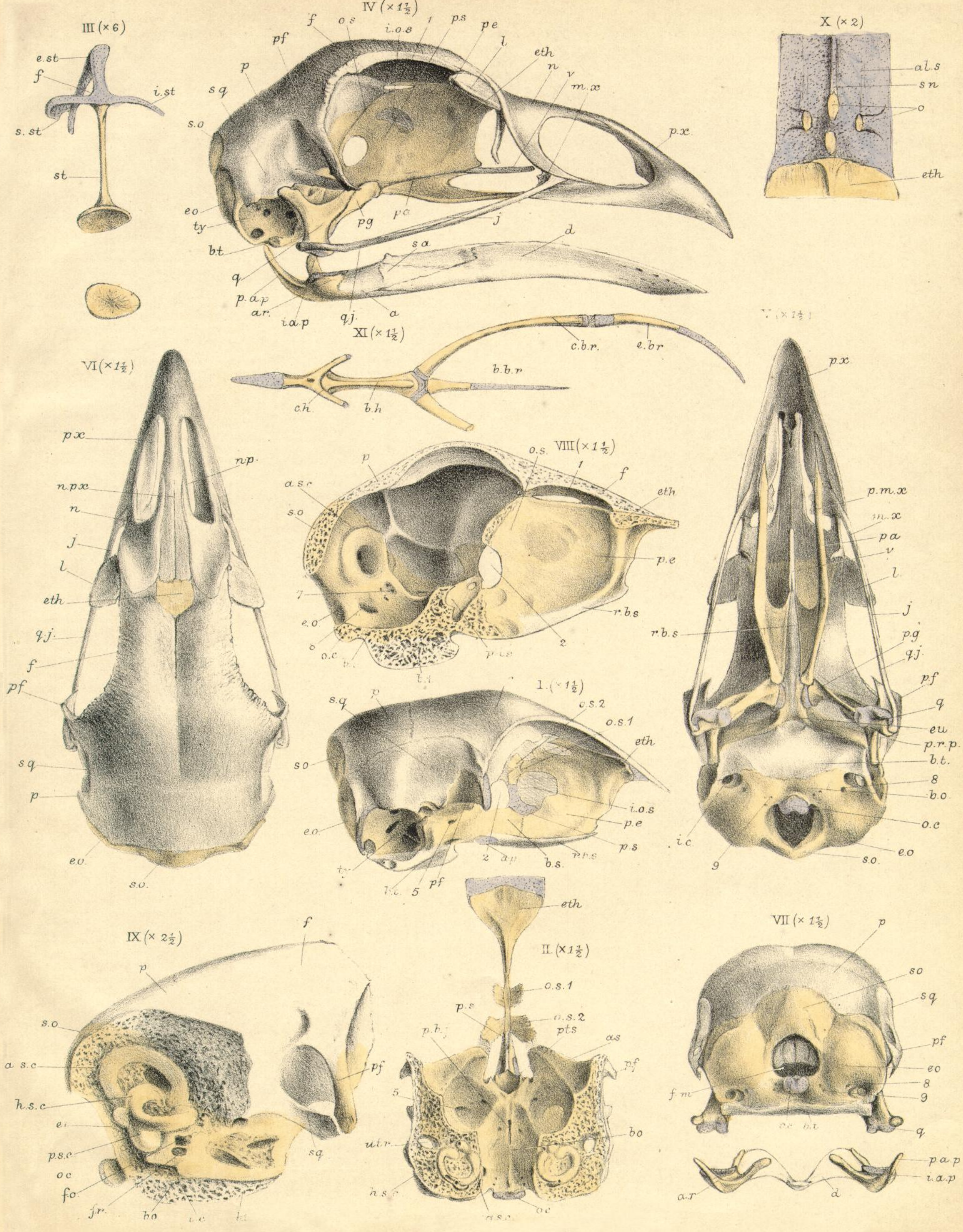
- Fig. 1. Vertical section of skull. $\times 3$ diameters.
 Fig. 2. Side view of occipital region. $\times 4\frac{1}{2}$ diameters.
 Fig. 3. Part of the same, seen obliquely. $\times 6$ diameters.

Eighth Stage.—Chicken 3 Months old.

- Fig. 4. Basal view of skull. $\times 2$ diameters.
 Fig. 5. Upper view of skull. $\times 2$ diameters.
 Fig. 6. Lateral view of skull. $\times 3$ diameters.
 Fig. 7. Posterior view of skull. $\times 2$ diameters.
 Fig. 7A. Inner view of head of quadrate. $\times 4$ diameters.

Ninth Stage.—Fowls 7 to 9 Months old.

- Fig. 8. Horizontal section of skull, from above. $\times 3$ diameters.
 Fig. 9. Horizontal section of skull, from below. $\times 2$ diameters.
 Fig. 10. End view of skull. $\times 2$ diameters.
 Fig. 11. Front view of skull. $\times 2$ diameters.



Fowl's Skull

PLATE LXXXVII.

Ninth Stage (continued).

- Fig. 1. Side view of skull. $\times 1\frac{1}{2}$ diameter.
- Fig. 2. Horizontal section of skull, upper view. $\times 1\frac{1}{2}$ diameter.
- Fig. 3. Stapes, lateral and basal views. $\times 6$ diameters.

Tenth Stage.—Old Fowls.

- Fig. 4. Side view of skull. $\times 1\frac{1}{2}$ diameter.
- Fig. 5. Basal view of skull. $\times 1\frac{1}{2}$ diameter.
- Fig. 6. Upper view of skull. $\times 1\frac{1}{2}$ diameter.
- Fig. 7. Posterior view of skull. $\times 1\frac{1}{2}$ diameter.
- Fig. 8. Sectional view of skull. $\times 1\frac{1}{2}$ diameter.
- Fig. 9. Side view of skull with auditory structures exposed. $\times 2\frac{1}{2}$ diameters.
- Fig. 10. Lower view of part of nasal septum. $\times 2$ diameters.
- Fig. 11. Os hyoides. $\times 1\frac{1}{2}$ diameter.